

EXPLORING THE POTENTIAL OF NEUROIMAGING USING NEAR INFRARED SPECTROSCOPY DURING COMPLEX CLINICAL URODYNAMICS

Hypothesis / aims of study

Functional near infra-red spectroscopy (fNIRS) is a non-invasive neuroimaging technique using near infra red lasers to deliver light to the brain via fiberoptic cables and optodes placed on the head. Absorption of the NIR light as it passes through brain tissue is a means of quantifying the changing concentration of deoxy-, oxy- and total haemoglobin in the pathway of the light. The technique can image up to 1cm deep into the cortex. fNIRS does not require the restrictive environment or positioning of the subject that fMRI and PET studies do, and the temporal resolution is better than these techniques allowing real time monitoring. Having identified the key regions of interest of brain-bladder control using fMRI [1], we used fNIRS to investigate brain responses during comprehensive urodynamic studies. Here we report on a study to explore the feasibility of using the fNIRS technique during urodynamics.

Study design, materials and methods

As such a feasibility study, 6 subjects aged >60 years with >5 episodes of urge urinary incontinence per week were recruited to undergo comprehensive, clinic-based urodynamic testing with simultaneous fNIRS. Informed consent from subjects was obtained. 25 NIRS optodes (8 light sources emitting at 690 and 830 nm, and 17 detectors [TechEn CW6 imager] giving 26 channels of information, Fig 1) were positioned in two sections to cover the pre-frontal cortex (PFC) and supplementary motor area (SMA). Comprehensive urodynamic testing including urethral pressure profiles, voluntary pelvic floor muscle contractions (PFMC), bulbocavernosus reflex (BCR) testing and repeated filling and voiding were carried out with simultaneous NIRS recording. Real-time changes in regional concentration of haemoglobin in the brain were recorded during spontaneous events such as detrusor overactivity, BCR and PFMC. Post-processing of fNIRS data comparing baseline to spontaneous events was used to produce maps of activation and deactivation of brain areas for qualitative comparison with fMRI data.

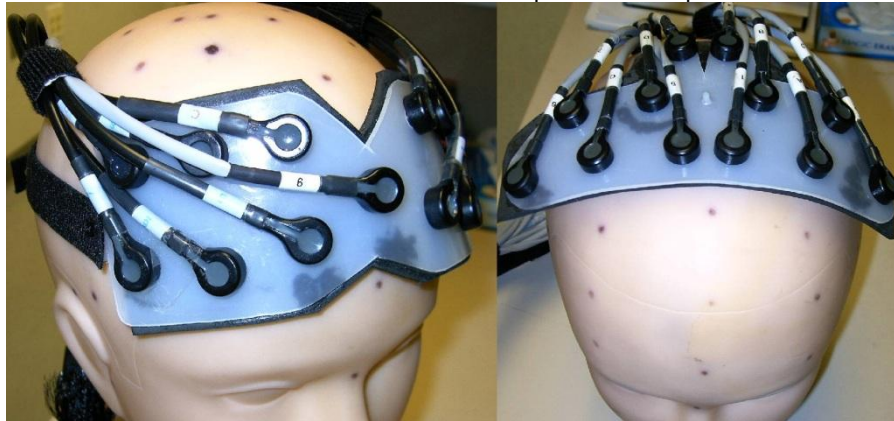


Fig 1, probe positioning.

Results

Relative changes in concentration of oxyhaemoglobin could be related to urethral sensation and to spontaneous UD events such as detrusor overactivity (DO) during real-time measurements of fNIRS signals and detrusor/urethral pressures. Figure 2 shows an increase in brain activity in the SMA during movement of the catheter while recording urethral pressure profiles, and subsequently a strong signal at DO, inhibited by sphincter contraction. Post-processed fNIRS signals show regional activity which is: increased in PFC and SMA during filling; decreased in these regions during voiding; increased in the medial PFC during BCR; and increased in the dorsolateral prefrontal cortex during DO (Fig 3).

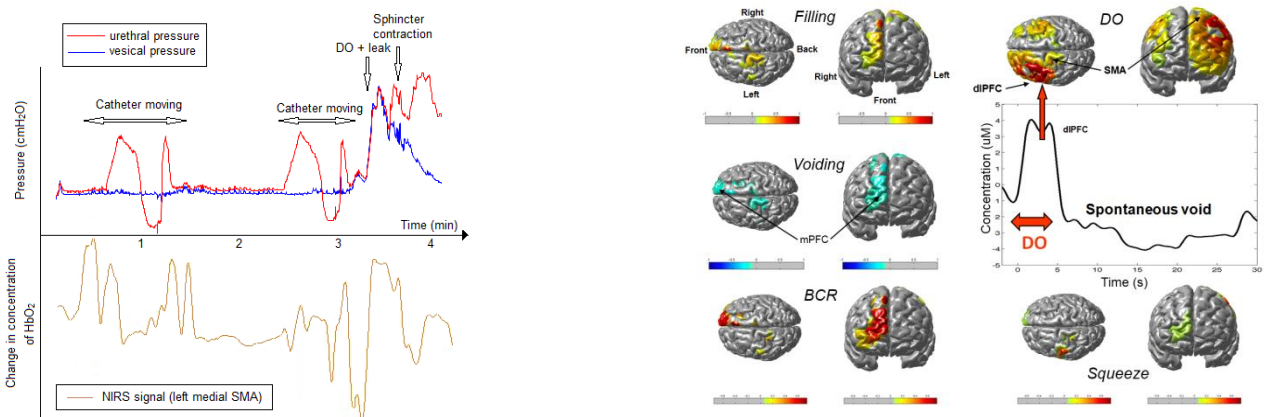


Fig 2, oxy-hemoglobin concentration in left medial SMA during movement of urethral catheter

Fig 3, regional activation during urodynamic events averaged over 3 subjects. Red scale shows activation, blue scale shows deactivations

Interpretation of results

The use of a NIRS cap during UDS was well tolerated by the subjects, and the number of optodes can in future be reduced to more specific areas to avoid artefact from movement of the optodes. Skin and/or hair pigmentation did not seem to be a barrier to good fNIRS signals. When mapping activity in specific brain regions, fNIRS shows activation and deactivation in regions of interest similar to fMRI studies, adding evidence to our current understanding of the brain-bladder model. Although these results have not yet reached statistical significance, this preliminary work is suggestive that fNIRS and fMRI are in broad agreement. Work to compare simultaneous fMRI and fNIRS is planned. fNIRS is a more flexible imaging tool than fMRI that is well tolerated by subjects, and can be used in a standard clinical environment indicating that cerebral activity can be monitored during more complex urodynamic testing than could be used in the MRI scanner, including voiding in normal position. fNIRS appears to resolve regional brain responses to spontaneous, short time-period urodynamic events in both the SMA and PFC and so may provide useful new real time information.

Concluding message

fNIRS is a useful technique that can add neuroimaging to urodynamics in normal clinical settings rather than the restrictive scanning positions/environments using PET/fMRI. It can be implemented rather easily, can provide real-time information about central control of urodynamic events, and may offer essential missing information.

References

1. Griffiths, DJ, Tadic, ST 2008, Neurourology & Urodynamics 27 (6) 466-474

<i>Specify source of funding or grant</i>	No funding for this study
<i>Is this a clinical trial?</i>	No
<i>What were the subjects in the study?</i>	HUMAN
<i>Was this study approved by an ethics committee?</i>	Yes
<i>Specify Name of Ethics Committee</i>	University of Pittsburgh Institutional Review Board
<i>Was the Declaration of Helsinki followed?</i>	Yes
<i>Was informed consent obtained from the patients?</i>	Yes