

PERINEAL BODY ANATOMY IN LIVING WOMEN: 3-DIMENSIONAL ENDOVAGINAL ULTRASOUND IMAGING

Hypothesis / aims of study

The study aim was to describe the characteristic complex anatomy of the perineal body using high resolution 3D endovaginal ultrasound (3D-EVUS).

Study design, materials and methods

The first part of this study was designed to identify perineal structures as seen on 3D EVUS performed in fresh cadavers. Fresh frozen pelves were prepared from unperfused/unfixed specimens. Immediately after the pelves were defrosted for 36 hours and brought to room temperature in an external bath, a 3D endovaginal ultrasonography was performed. BK Medical (Peabody, MA) with a 2050 probe with 3D imaging technology was used for acquisition of images. Echogenic structures suspicious for being superficial transverse perinei, puboperinealis, puboanalis, and the EAS were tagged with biopsy needles (MPM Medical, Elmwood Park, NJ) and marked with one cubic centimeter of indigo carmine dye for localization. 44 nulliparous asymptomatic females were imaged with 3D-EVUS using a 9-16 MHz rotational 360° transducer. Analyses were conducted off-line from stored 3D volumes. Anatomic structures were analyzed in axial, sagittal, and coronal slices using a standardized technique.

Results

The perineal body is best visualized on sagittal scans, appearing as a pyramidal, mixed echogenicity structure in the midline between rectum and vagina. In the axial plane, the relationship of the lower portion of the perineal body with the superficial transverse perineal muscle, the bulbospongiosus muscle and the external anal sphincter are appreciated (Fig 1). In the same plane, the upper portion of the perineal body appears in direct contact with the pubovisceral components (puboperinealis muscle and puboanalis muscle) of the levator ani (Fig 2).

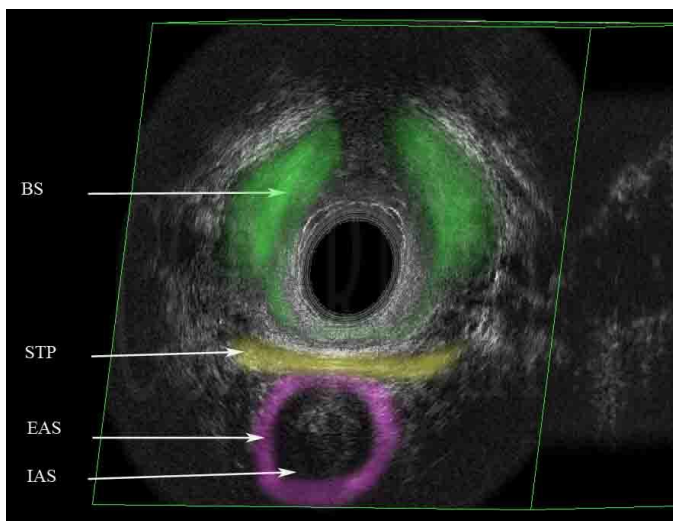
Interpretation of results

High resolution 3D-EVUS readily visualizes characteristic anatomical features of the perineal body as described by MRI studies (1).

Concluding message

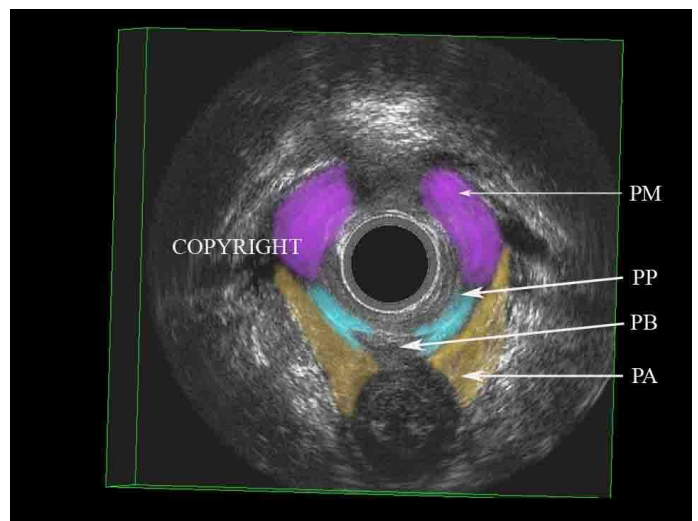
This study describes the complex anatomy of the perineal body as seen in 3D-EVUS of nulliparous women with normal support and no pelvic floor dysfunction. This study serves as a comparison of the perineal body structures in women with pelvic floor pathology.

Fig 1.



Low level anatomy of the perineal structures

Fig 2.



Mid level anatomy of the perineal structures

Legends: BS: Bulbospongiosus muscle, STP Superficial transverse perinea, EAS: External anal sphincter, IAS: Internal anal sphincter, PB: Perineal membrane, PP: Puboperinealis, PA: Puboanalis

Specify source of funding or grant	None
Is this a clinical trial?	No
What were the subjects in the study?	NONE