

3-DIMENSIONAL ENDOVAGINAL ULTRASONOGRAPHIC IMAGING OF VAGINAL MASSES

Hypothesis / aims of study

3-Dimensional endovaginal ultrasound (3D EVUS) is an emerging technology in evaluation of pelvic floor disorders [1]. Diagnosis of vaginal cysts and masses can be difficult and the etiology is often clarified at the time of surgery [2]. 3D EVUS for visualization of vaginal masses has not been reported in the literature. Our aim was to assess interrater reliability of vaginal masses evaluated by 3D endovaginal ultrasonography.

Study design, materials and methods

A retrospective review of 3D EVUS performed at three institutions was performed. The 3D EVUS was performed in patients with varied pelvic floor complaints. Patients' history was reviewed to assess if any other imaging modality had been used for comparison, if surgery was performed, and what the surgical or pathologic findings were. The scans were reviewed by two reviewers and interrater reliability was established. For comparison of clinical diagnosis and ultrasound diagnosis a $P < .05$ was deemed as significant. Cohen's kappa index and 95% confidence intervals were assessed. Kappa values of 0.8–1.0 were considered excellent agreement, of 0.6–0.8 good, of 0.4–0.6 moderate, 0.2–0.4 fair, and of less than 0.2 poor.

Results

38 patients with pelvic floor mass had undergone 3D EVUS. The patients had the mean age of 44 (range 19-72). 34/38 (89%) were Caucasian, and 4/38 (10%) were African American. 9/38 (24%) were nulliparous. The patients had the following presentations: 21/38 (55%) mass, 18/38 (47%) pain, 7/38 (18%) dyspareunia, 3/38 (8%) prolapse, 2/38 (5%) urinary incontinence, and 2/38 (5%) were asymptomatic. By clinical exam, the following diagnoses were made: 2/38 asymptomatic, 11/38 vaginal mass, 7/38 urethral diverticulum, 1/38 hematoma, 7/38 Bartholin gland cyst, 9/38 had miscellaneous or no diagnosis. By ultrasound examination, the following diagnoses were made: 12/38 had urethral diverticulum, 5/38 had a hematoma, 10/38 had a Bartholin gland cyst, and 10/38 had miscellaneous diagnosis (Table 1). 28/38 (74%) underwent surgery and diagnosis were confirmed. 8/38 (21%) had other imaging modalities, 3/8 were negative despite positive 3D EVUS findings. 10/38 (26%) were managed conservatively. 23/38 (61%) patients with unclear clinical diagnosis had their diagnosis clarified by ultrasound ($P < .0006$). 7/13 patients with urethral diverticulum had correct clinical diagnosis. Most anterior vaginal masses were diagnosed by ultrasound as urethral diverticulum. One clinical urethral diverticulum was diagnosed as a paravaginal defect; one was diagnosed as a solid mass with final pathology of angiosarcoma, and another one as an urethrovaginal fistula (Table 2). Bartholin gland cysts' clinical and 3D EVUS were not significantly different ($P = .24$). Only 1 patient had presenting clinical diagnosis of a hematoma. 3 patients with complaint of pressure, and one with complaint of a vaginal mass had ultrasound diagnosis of hematoma. Interobserver reliability (Cohen's kappa) for ultrasound diagnosis was (ICC 0.888, CI 0.778 - 0.944) signaling significant agreement between the readers.

Interpretation of results

Clinical diagnosis was accurate for diagnosis of symptomatic Bartholin glands. 3D EVUS diagnosed asymptomatic Bartholin glands as well. 3D EVUS was most useful in diagnosing correct etiology of otherwise elusive vaginal masses. 3D EVUS diagnosis is reliable between 2 readers.

Concluding message

The ease by which a 3D EVUS ultrasound can be performed in a clinical setting provides an opportunity to investigate vaginal masses in patients more quickly than is feasible with a CT scan or an MRI.

Table 1.

Diagnosis	Clinical	Ultrasound
None	3	0
Vaginal mass	11	0
Urethral diverticulum	7	13
Hematoma / Seroma	1	5
Bartholin gland cyst	7	10
Other diagnosis	9	10
Total	38	38

Table 2.

Final Diagnosis by Ultrasound	Number
Bartholin gland cyst	10
Gartner duct cyst	1
Paravaginal cyst	1
Rectovaginal septum cyst	5
Suburethral angiosarcoma	1
Seroma / Hematoma	5
Urethral diverticulum and fistula	1
Urethral diverticulum	13
Vaginal cancer with rectal infiltration	1
Total	38

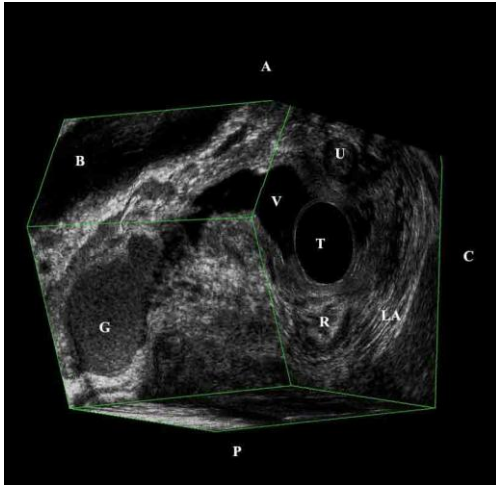


Figure 1.

Copyright

A Gartner duct cyst with mixed echogenic content is demonstrated through a post-processed inferolateral view showing its long tortuous course into the right pelvic side wall.

References

1. Shobeiri SA, LeClaire E, Nihira MA, Quiroz LH, O'Donoghue D. Appearance of the Levator Ani Muscle Subdivisions in endovaginal 3-Dimensional Ultrasonography. *Obstet & Gynecol* 2009;114:66-72.
2. Romanzi LJ, Groutz A, Blaivas JG. Urethral diverticulum in women: diverse presentations resulting in diagnostic delay and mismanagement. *J Urol.* 2000;164(2):428-33.

Specify source of funding or grant	None
Is this a clinical trial?	Yes
Is this study registered in a public clinical trials registry?	No
Is this a Randomised Controlled Trial (RCT)?	No
What were the subjects in the study?	HUMAN
Was this study approved by an ethics committee?	Yes
Specify Name of Ethics Committee	The University of Oklahoma HSC IRB # 15236
Was the Declaration of Helsinki followed?	Yes
Was informed consent obtained from the patients?	No