

# Gracilis Flap for Recurrent Urethrovaginal Fistula

## HYPOTHESIS / AIMS OF STUDY

- **Recurrent Urethrovaginal fistula (UVF)** is uncommon.
- The **Aim** : to consider a reliable procedure and a good alternative technique for repair of recurrent urethrovaginal fistula and restore Quality of Life.



FIGURE 1: PRE OP: Pooling of Urine in Vagina

## STUDY DESIGN, MATERIALS AND METHODS

- History : urinary and fecal incontinence.
- Initial management in a remote hospital : Colostomy. and repair of urethrovaginal fistula. Failed TWOC with raised post void residual
- Imaging, . Examination and UrethroCystoscopy : A large defect up to proximal urethra, with cicatrized vagina

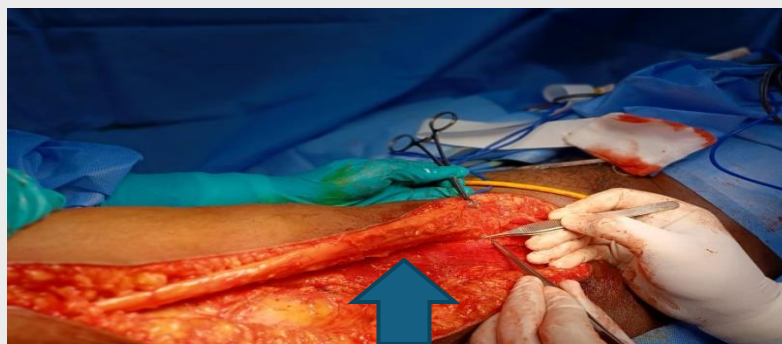


FIGURE 2: INTRA OP: Gracilis muscle Flap Incision in the mid thigh. Adequate length of the flap Tunneled, subcutaneous to the area of defect up to bladder neck and positioned well with absorbable sutures.

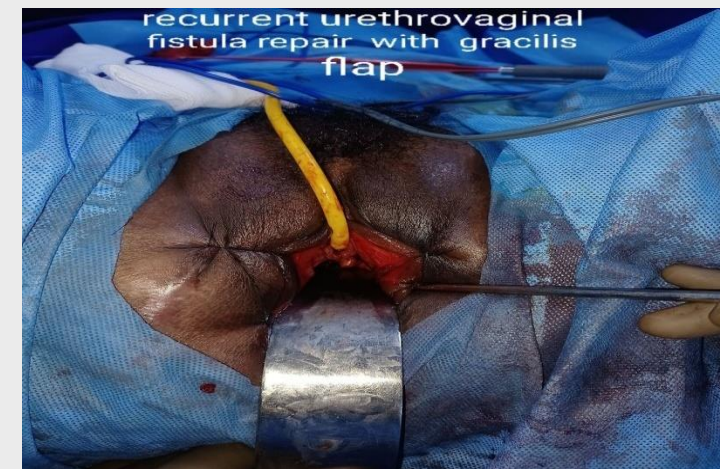

FIGURE 3: POST OP: Suprapubic catheter was removed after six weeks and Urethral Catheter was removed after eight weeks post op.

## RESULTS

- Voiding well with alpha blocker and short term muscle relaxant.
- Initially ,Clean intermittent self catheterisation.

## INTERPRETATION OF RESULTS

- **THE TECHNICAL CHALLENGE** WITH ATRETIC VAGINA: TO CREATE A SPACE FOR THE GRACILIS FLAP .
- FLAP PROVIDES **GOOD VASCULARITY**, ADEQUATE COVERAGE ,**CUSHION AND SLING EFFECT** FOR THE LARGE DEFECT AND AT THE BLADDER NECK.

## CONCLUDING MESSAGE

- Evaluate the **type and extent** of the urethrovaginal fistula and recurrence factor
- Assess if continence procedure is required.
- Gracilis muscle flap repair with expertise can be considered as a **good alternative for large defects** with recurrent urethrovaginal fistula .
- An ideal choice in **restoring continence and Quality of Life**.

**Gopi Shyamala<sup>1</sup>**, Paul Rajesh<sup>1</sup>,  
Praveenkumar L<sup>2</sup>

1. Apollo Hospitals, Dept of Urology  
Chennai
2. Apollo Hospitals, Dept of Plastic Surgery,  
Chennai