

## DO NEAR INFRARED SPECTROSCOPY (NIRS) AND FUNCTIONAL MRI AGREE WHEN INVESTIGATING BRAIN CONTROL OF THE LOWER URINARY TRACT?

### Hypothesis / aims of study

Urge urinary incontinence (UUI) among older adults is prevalent, morbid, and costly and its pathophysiology remains elusive. Traditional studies of UUI have focused largely on the bladder but recent studies have begun exploring the brain's role in controlling both the bladder and the urethra using PET and fMRI studies[1,2]. These imaging techniques require that subjects be studied while supine, and technical limitations can preclude simultaneous detailed examination of lower urinary tract function; reproducing symptoms can be difficult. Functional near infra-red spectroscopy (fNIRS) is an optical brain imaging technique that has no exposure to ionizing radiation or limitation due to metal implants or equipment. It allows cortical brain activity (up to 1 cm into the brain) to be measured in any posture and clinical environment. Because it also allows concurrent urodynamic evaluation of the urinary tract, it may offer a way to more comprehensively investigate UUI's pathophysiology. fNIRS has poor spatial resolution, but good signal to noise ratio and temporal resolution allowing real time tracking of changes in brain activity. Previous fMRI studies have localised areas that are important for continence control, allowing design of a NIRS probe to target these areas. In a pilot study, fNIRS was found to feasibly measure hemoglobin concentration in cortical brain areas during rigorous clinical urodynamic investigations. Thus, we conducted the present study to evaluate how closely brain activation detected by NIRS corresponds to that seen during fMRI, the current gold standard for studying brain/bladder control.

### Study design, materials and methods

6 women (>60 years) regularly experiencing UUI and demonstrating detrusor overactivity (DO) on urodynamic studies were recruited. BOLD (Blood oxygen level dependent) fMRI sequences and fNIRS measurements (oxy, de-oxy and total haemoglobin) were acquired simultaneously during repeated bladder fill and withdraw cycles (24ml infused in 12 seconds followed by 21ml withdrawn in 12 seconds) of a low volume bladder (little/no sensation) and a high volume bladder (sensation of 'urgency'). fNIRS signals were collected bilaterally from the supplementary motor area (SMA), superior temporal gyrus (STG) and dorsolateral prefrontal cortex (dlPFC), areas known to be important in the micturition cycle from previous studies. fMRI data was analysed using SPM5 (Wellcome trust, UK), and NIRS data was analysed using in house software. Regional brain activity was identified as the contrast between infusion and withdrawal conditions in both methods; this is an established procedure for investigating bladder filling within an MRI scanner. 'Urgency' was defined by subject signal. Activity was averaged over the group for both non-urge and 'urgency' conditions. fNIRS (oxyhaemoglobin) was compared to fMRI BOLD signals to confirm technique validity in these groups.

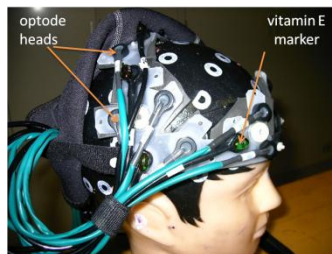


Figure 1, picture of NIRS cap on model head. 'Vitamin E' markers denote light sources on MRI images.

### Results

During the non urge condition there was some activation in the right SMA which became stronger in the 'urgency' condition. In total there were seven blocks of infusion-withdraw cycles where the subjects experienced, and signalled, strong 'urgency'. The fNIRS oxy-Hb activity rendered onto a brain surface is shown in figure 2, compared with the fMRI BOLD signal (coronal and sagittal slices though SMA) shown in figure 3. This area of strong activation is circled and agrees in both methods.

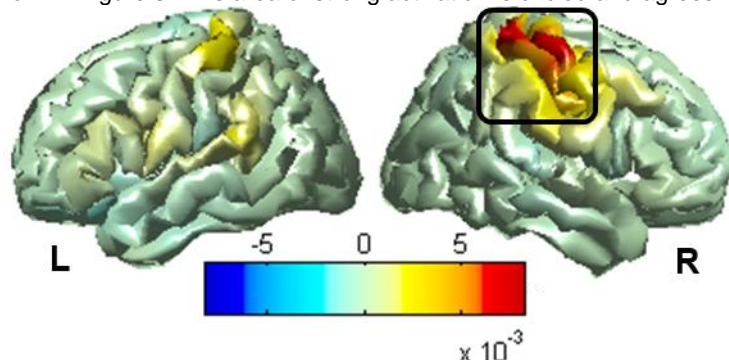


Figure 2, 'Activation' (increased oxy-haemoglobin concentration) in the brain, shown in red in the right SMA, as measured by fNIRS during the 'urgency' condition. Infusion minus withdrawal contrast is used for direct comparison to fMRI studies.

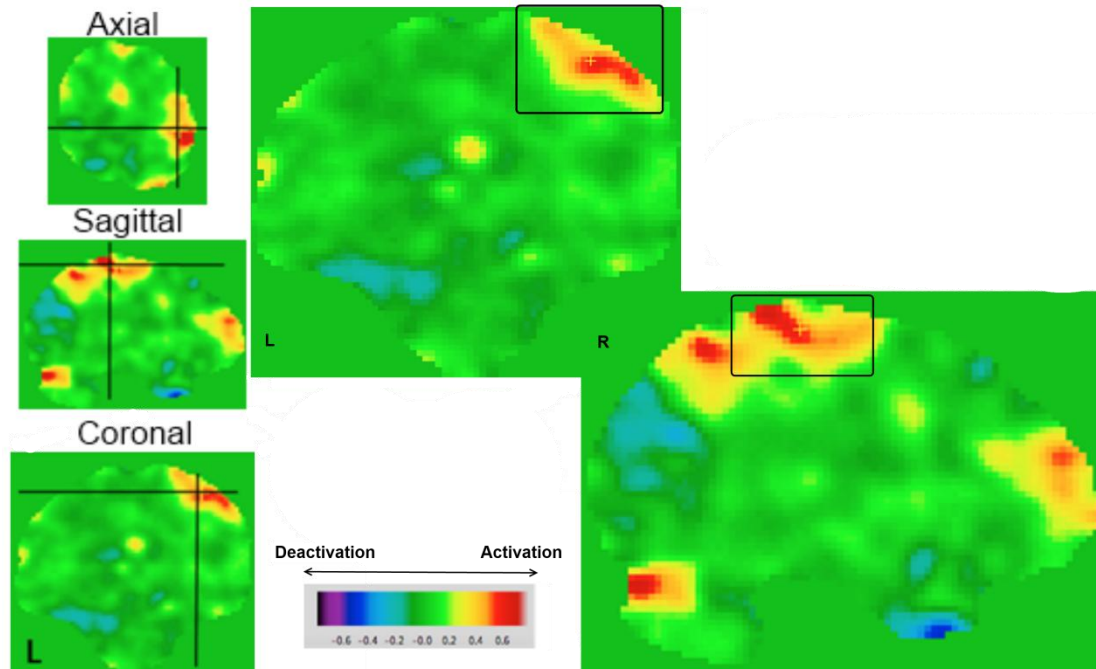


Figure 3, Corresponding activation shown in an fMRI contrast image (infusion minus withdrawal during the same 'urgency' condition). Sections show activation (red) in the same right sided SMA as the NIRS image in figure 2.

#### Interpretation of results

Areas of strong activation seen in the fNIRS oxy-HB measurements were also seen in fMRI contrast images in a similar location. Since the direction (increase or decrease) and location of change in activity are consistent, the two methods can be said to agree sufficiently to compare the results of fMRI studies (primarily concerned with the locations of activity corresponding to a stimulus) with those of NIRS.

#### Concluding message

fNIRS and fMRI agreed as to location of areas of strong activation during 'urgency'. fNIRS can be used in clinical urodynamic situations to add relevant information about central control, and the results may be compared to the current knowledge based on fMRI. The addition of fNIRS to urodynamic studies opens up new possibilities for functional lower urinary tract studies.

#### References

1. Griffiths DJ, Tadic SD, 2008 Neurourology and Urodynamics 27 (6) 466-474
2. Blok BF et al 1997 Brain 120(1)111-121

#### Disclosures

**Funding:** University of Pittsburgh Institute on Aging Pilot grant **Clinical Trial:** No **Subjects:** HUMAN **Ethics Committee:** University of Pittsburgh Institutional Review Board **Helsinki:** Yes **Informed Consent:** Yes