

## BEHIND THE ULCER TYPE IC – AN ANALYSIS OF THE CORRELATION AMONG CLINICAL SYMPTOMS, IMMUNOCHEMICAL STUDY, COMPUTERIZED TOMOGRAPHY, AND HISTOPATHOLOGY FINDINGS BETWEEN ULCER AND NON-ULCER TYPE IC/BPS

### Hypothesis / aims of study

Current consensus suggests the patients with interstitial cystitis(IC)/bladder pain syndrome (BPS) could be subdivided into two types, ulcerative and non-ulcerative. The clinical characteristics in the patients with ulcerative and non-ulcerative IC/BPS are different, but the pathophysiology and underlying mechanism difference between these patients were still unclear. The objective of this study is to investigate the difference in the patients with ulcerative and non-ulcerative IC/BPS.

### Study design, materials and methods

Fourteen female ulcer IC/BPS patients and 14 age-matched non-ulcer IC/BPS patients who were admitted for cystoscopic hydrodistention were enrolled into this study. The clinical symptoms and urodynamic study results were recorded. Computer tomography (CT) was investigated in the ulcer IC/BPS patients. Bladder mucosa biopsy was taken during the procedure and sent to a pathologist for histopathology review. The bladder specimen inflammation severity, eosinophil infiltration and urothelium denudation under hematoxylin and eosin stain was graded on a 4-point scale (0: none, 1: mild, 2: moderate, and 3: severe). Immunofluorescence staining and quantification of the adhesion protein E-cadherin, tryptase, zona occludens-1 (ZO-1) for the bladder specimens were carried out. Specimens were investigated for muscarinic receptors M2, M3, e-NOS and P2X3 with Western blotting.

### Results

The mean age of ulcer and non-ulcer IC/BPS patients were 57.9 and 56.5 years old, respectively. Compare to non-ulcer IC/BPS, ulcer IC/BPS patients had significantly higher mean VAS pain score ( $7.8\pm 2.3$  vs  $3.4\pm 3.1$ ,  $p=0.006$ ), smaller cystometric bladder capacity ( $133.4\pm 68.2$  mL vs  $254.9\pm 136.2$  mL,  $p=0.013$ ) and smaller urge sensation volume ( $108.5\pm 43.2$  mL vs  $205.6\pm 74.1$  mL,  $p=0.013$ ) during urodynamic study. However, the O'Leary-Sant symptom scores between two groups did not have significant difference. Ten of 14 ulcer type IC/BPS patients had focal thickening bladder wall in CT while no focal wall thickening was found in any non-ulcer IC/BPS (Fig. 1). The ulcer IC/BPS bladder specimens have more severe or moderate eosinophil infiltration (5/14 vs 0/14,  $p=0.04$ ) and urothelium denudation (6/14 vs 0/14,  $p=0.016$ ) than non-ulcer IC/BPS bladder (Fig. 1 and Table 1). The E-cadherin expression was significantly lower, TUNEL and e-NOS expression are significantly higher in the ulcer IC/BPS bladder than that in non-ulcer IC/BPS (Table 2). The patients with moderate to severe urothelium denudation had higher VAS pain scale ( $7.1\pm 2.7$  vs  $3.2$  vs  $4.0$ ,  $p=0.048$ ), smaller urge sensation volume ( $131.1\pm 51.8$  mL vs  $275.5\pm 70$  mL,  $p=0.006$ ) and a higher TUNEL expression than the patients with none to mild denudation ( $5.9\pm 3.5$  vs  $2.0\pm 1.4$ ,  $p=0.022$ ).

### Interpretation of results

The patients with ulcer IC/BPS had more severe clinical symptoms in VAS pain scale, specific focal bladder wall thickening in CT image, bladder eosinophil infiltration and denudation in histopathology examination, higher cell apoptosis, urothelial dysfunction and inflammation in immunochemical staining than non-ulcer IC/BPS. And the histopathology finding of urothelium denudation could be correlated to clinical symptoms and immunochemical staining.

### Concluding message

Ulcer and non-ulcer IC/BPS are similar clinical syndrome with different symptoms severity, image, histopathology and immunochemical findings. Ulcer and non-ulcer IC/BPS might be considered as two different diseases, and the pathogenesis difference should be investigated.

Fig. 1. Histopathology and CT finding of ulcer IC/BPS: (A) urothelium denudation with inflammatory cells infiltration (100X, H&E stain); (B) eosinophil infiltration (arrowhead) (400X, H&E stain); (C) focal thickening in right lateral wall (white arrow).

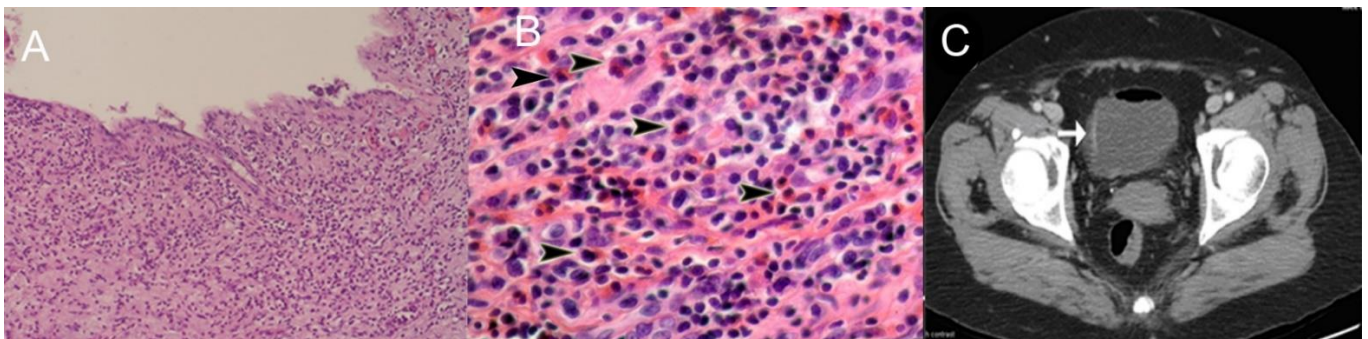


Table 1. Histopathology findings of ulcer and non-ulcer IC/BPS

	inflammation				Eosinophil infiltration				Urothelium denudation			
	none	mild	mod	severe	none	mild	mod	severe	none	mild	mod	severe
Ulcer IC/BPS	0	10	3	1	7	2	2	3	0	9	2	3
Non-ulcer IC/BPS	9	5	0	0	14	0	0	0	8	6	0	0

Table 2. Immunochemical staining results in the ulcer and non-ulcer IC/BPS

	Ulcer IC/BPS (N=14)	Non-ulcer IC/BPS (N=14)	P-value		Ulcer IC/BPS (N=14)	Non-ulcer IC/BPS (N=14)	P-value
E-cadherin	12.71±9.77	25.00±13.30	0.011	M2	1.28±2.29	1.05±0.48	0.074
tryptase	5.87±5.16	8.93±6.40	0.141	M3	0.28±0.09	0.34±0.07	0.935
ZO-1	5.37±5.80	3.68±3.37	0.405	P2X3	1.10±0.56	2.00±1.54	0.273
TUNEL	3.83±3.21	1.80±1.82	p=0.05	e-NOS	0.46±0.32	0.07±0.08	<0.001

Disclosures

**Funding:** NONE **Clinical Trial:** No **Subjects:** HUMAN **Ethics Committee:** Hualien Tzu Chi Hospital, Buddhist Tzu Chi Medical Foundation, Research Ethics Committee **Helsinki:** Yes **Informed Consent:** Yes