

SLING INCISION MAY NOT BE THE END OF THE STORY!

Hypothesis / aims of study

To assess the presentation and management of women with residual lower urinary tract symptoms (LUTS) after prior mid-urethral sling (MUS) incision.

Study design, materials and methods

Following IRB approval, a prospective longitudinal MUS removal database was reviewed for non-neurogenic women who presented with continued LUTS despite a prior sling incision. Data collection included demographics, presenting symptomatology, management with sub-urethral MUS excision, and outcomes using electronic medical records. Data was reviewed by a neutral investigator not involved with patient care.

Results

From a database of 361 patients who underwent sling removal between 2006-2014, a total of 12 women were identified who had sling incision prior to referral. Mean age was 59 ± 17 years, with mean BMI of 30 ± 7 . Median time from initial MUS placement to sling incision was 5 months (range 2-78). Based on operative note, two patients had right sided incision, 1 a midline incision and in 9 patients incision site was not specified. After incision, 4 were treated with anti-cholinergic medications for urge incontinence (UUI), while one received a sacral neuromodulator. In addition to those 5 with UUI, 2 had persistent stress urinary incontinence (SUI), and 2 mixed urinary incontinence (MUI). Evaluation included standing voiding cystourethrogram (10) with lateral views, with urethral distortion with mid-urethral kinking noted in five; trans-labial ultrasound (2) (Figure 1); and multichannel urodynamics (5) demonstrating obstruction (3) and valsalva voiding (2). Indications for MUS excision were persistent obstruction (2), obstruction and pain (1), persistent vaginal pain/dyspareunia (4), recurrent vaginal extrusion/dyspareunia (3), worsening urge incontinence (UUI) (1) and urethral erosion (1). Median time from incision to sling excision was 16 months (range 3-51). Type of sling included transobturator tape (4), retropubic sling (5) and minisling (3). Median follow-up after MUS excision was 18 months. One patient was lost to follow-up. Voiding dysfunction was cured in all 3 as did extrusion in 3, while vaginal pain and dyspareunia improved in 2 and UUI improved in 1. Three women had persistent SUI and 2 developed recurrent SUI. Two women were treated satisfactorily with bulking agents, and one with bulking agent followed by a rectus fascial sling.

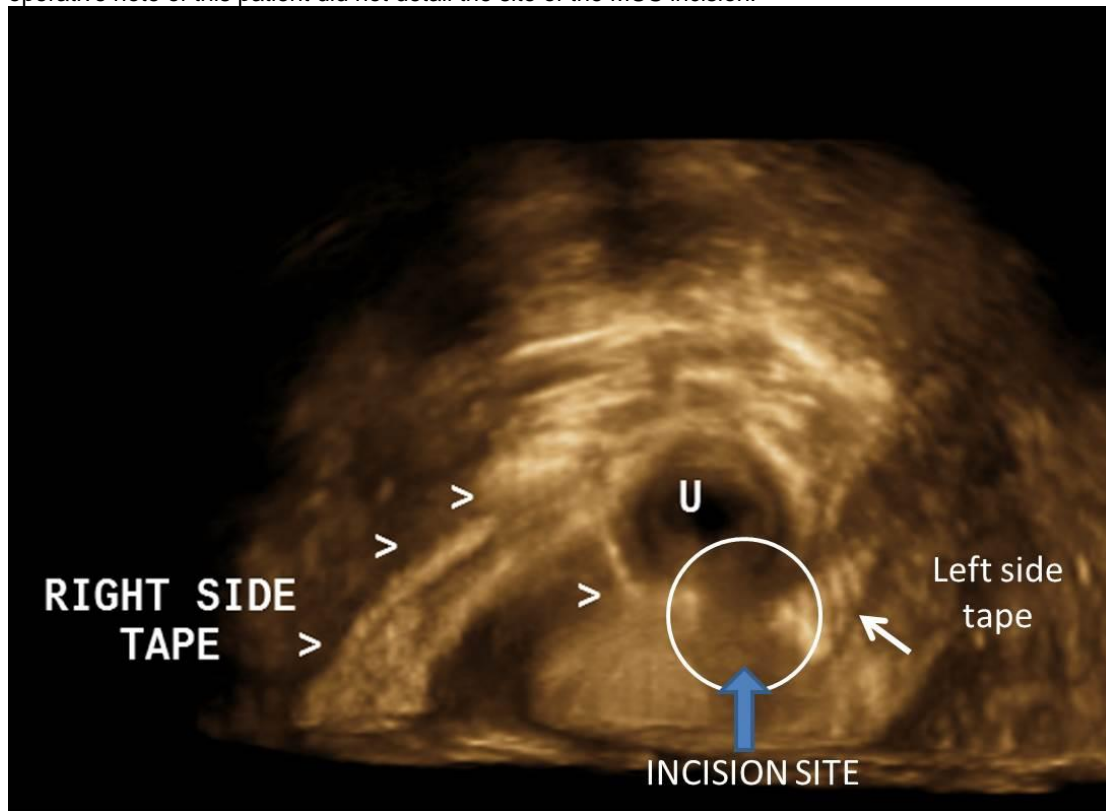
Interpretation of results

Although it is unknown how many patients do well after a MUS incision alone, this series alerts to the fact that a subset of women may experience residual LUTS dominated by UUI, obstruction, and pain/dyspareunia. Because of the prior history of MUS incision, it is commonly assumed by the treating team that the MUS is not causing this persistent symptomatology. There is typically a substantial delay in recognition and a range of therapies offered to these women with no durable benefit. Therefore, it is important to recognize that not all MUS incisions will be successful in relieving LUTS and that, following detailed evaluation and possible specialized testing, MUS excision should be considered in those with residual LUTS.

Concluding message

Sling incision may not always resolve LUTS. In a subset of women, sling excision may eventually be needed.

Figure 1. Translabial three dimensional ultrasound demonstrating the course of a transobturator tape with left and right sided arms separated by a groove at the 5-6 o'clock position inferior to the urethral lumen where the prior incision took place. The operative note of this patient did not detail the site of the MUS incision.



Disclosures

Funding: None **Clinical Trial:** No **Subjects:** HUMAN **Ethics Committee:** University of Texas institutional Review Board
Helsinki: Yes **Informed Consent:** Yes