

THE FIRST RANDOMIZED CONTROLLED TRIAL COMPARING LASER AND TOPICAL STEROID TREATMENTS FOR LICHEN SCLEROSUS ET ATROPHICUS, PRELIMINARY RESULTS

Urska Bizjak-Ogrinc¹, Sabina Sencar¹, Adolf Lukanovic², Zdenko Vizintin³

1. Juna Clinic, 2. Division of Gynecology Clinic at University Medical Centre Ljubljana, 3. Fotona

Hypothesis / aims of study

The purpose of this clinical study was to evaluate the use of new laser treatment of lichen sclerosus (LC) and to compare it with topical steroids (TS) therapy. The main objectives of our study were to assess the efficacy and safety of this novel laser therapy to see if it could become a minimally invasive alternative for this indication.

Study design, materials and methods

In this randomized controlled prospective study conducted between January 2016 and March 2017 at two medical centres in Slovenia, patients older than 18 years with diagnosed lichen sclerosus were randomly assigned to the intervention or control group of 20 patients each. Study group received three laser treatments every 14 days, while the control group was receiving topical corticosteroids for 3 months. Laser treatment consisted of combination of non-ablative 1064 nm NdYAG laser using super long non-ablative pulses followed by 2940 nm short pulse fractional ablative ErYAG laser. The improvement was assessed with: biopsies; clinical pictures and the severity of lichen symptoms (burning, itching, tingling and pain using VAS (1-10). Treatment discomfort was evaluated with VAS (0-10) at each session. After every treatment session as well as at every follow-up lichens were visually inspected and photographed and the patients were interviewed about satisfaction and improvement of sexual function as well as about adverse effects. Follow-ups (FU) were scheduled at 1, 3, 6 and 12 months.

Results

40 patients were randomized into study group (laser, A) and control group (topical steroid, B) with 20 patients each. All patients from laser and 18 patients from control group were completed the treatments and were followed up so far for the first 3 months. Severity of lichen symptoms reduced significantly in both group, but more in laser group: burning went from 5.5 to 0.3 at 3M FU in group A and from 7.7 to 3.9 in B group; pain reduced from 6.6 to 0.5 in A group and from 5.5 to 3.3 in B group; itching: group A – 7.1 to 0.7, group B – 8.6 to 5.5 and tingling: group A – 2.1 to 0.3, group B – 3.7 to 1.3. Sexual function significantly improved in laser group (only 10% of patients complained of dyspareunia at 3M FU in comparison of 55% at baseline and 15% of anorgasmia vs.40% at baseline) but not also in group B (dyspareunia: 67% at 3M FU and 44% before; anorgasmia: 40% at 3M FU and 39% before). Biopsies showed the presence of the LC in 100% of patients in group A and 89% in group B at the baseline and in 50% in group A and 60% in group B at 3M FU. All patients from laser group were very satisfied with results at 3M FU, while the group B had 13% very satisfied and 33% satisfied patients; 27% were somehow satisfied and 27% not satisfied. Laser treatment discomfort was very low (at Tx1: 0.65, at Tx2: 0.2 and at Tx3: 0.0) and all adverse effects were mild and transient.

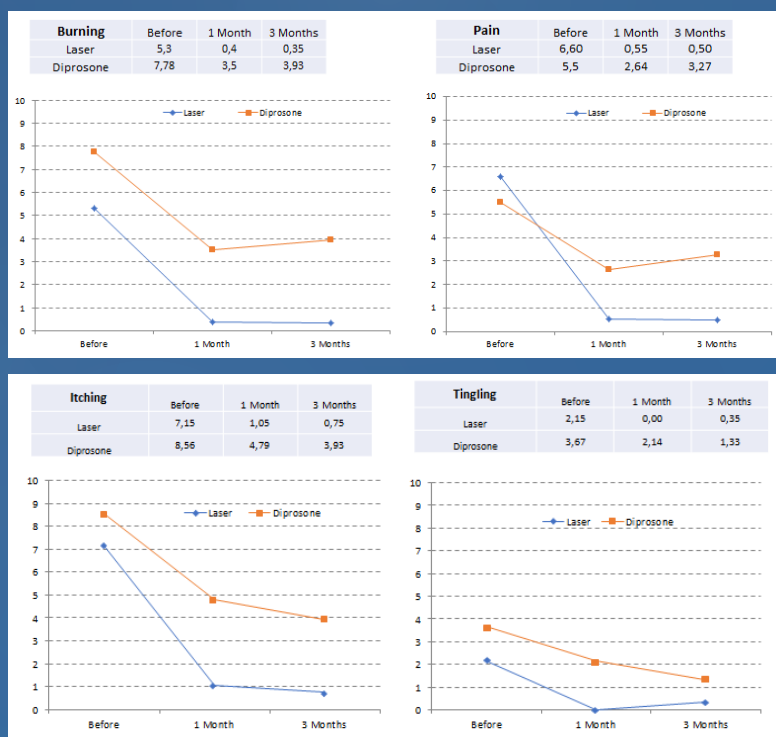

Fig.1 Severity of Lichen Symptoms: Burning, Pain, Itching, Tingling (VAS 0-10)

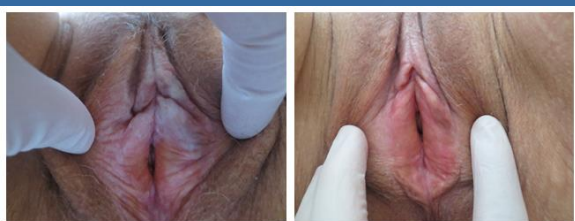


Fig.3 Before (left) and 3 months after (right) laser treatment

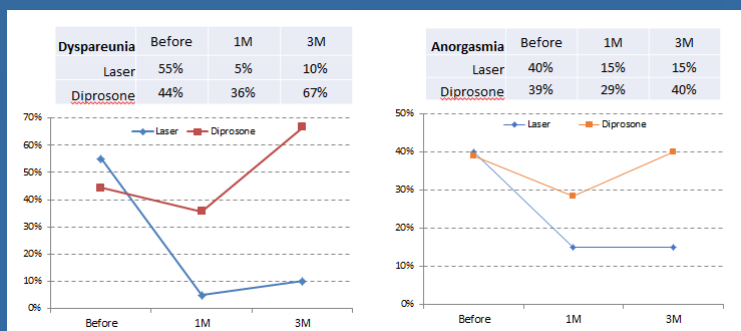


Fig.2 Sexual Function – Dyspareunia during the intercourse (Yes/No); Anorgasmia (Yes/No)

Interpretation of results and concluding message

The preliminary results of this study have shown that laser treatment is improving all the symptoms of LC as well as sexual function and that improvement is better than with topical steroids. Patients' didn't report any significant discomfort during the treatment and their satisfaction with results was very high.

In spite of limitations of this study due to a small number of patients and short follow-up, the use of this laser procedure seems to be a safe and efficacious method for treatment of lichen sclerosus. Nevertheless more controlled studies should be performed to confirm the promising findings of the preliminary stage of our study.