

# What are the long term consequences of recreational ketamine misuse on the urinary tract?

Néha Sihra, Simon Rajendran, Jeremy Ockrim, Dan Wood

Department of Urology, University College London Hospital, London, UK



## Introduction

Regular use of recreational ketamine causes severe damage to the urinary tract in up to 30% of patients.

Patients present with a spectrum of debilitating symptoms – most notably pain - alongside urinary frequency, haematuria and obstructive nephropathy.

The aim of this study was to evaluate management strategies and outcomes in patients undergoing surgical intervention following damage to their urinary tract associated with ketamine use.

## Methods

A retrospective review, of prospectively collected data (2007 and 2015) was performed.

Evaluation included CT urogram, cystoscopic evaluation of bladder capacity +/- biopsy.

Indications and outcomes for surgical intervention were assessed.

## Results

42 patients were identified. 63% were male and mean age at presentation was 28.7 (range 23-55).

All bladder biopsies confirmed an eosinophilic inflammatory infiltrate. A significant proportion of patients (83.3%) were found to have reduced cystoscopic and functional bladder capacity of <300 ml (mean 190 mls, range 70-550).

29 patients were treated conservatively with a view to symptom resolution. 2 patients underwent dilatation for urethral strictures. 4 patients underwent repeated injections of intra-detrusor Onabotulinum Toxin A with minimal subjective symptom relief. 2 of these patients proceeded to have major reconstruction.

13 patients underwent major surgical reconstruction. Of these patients 53.8% (7/13) had one or more complications requiring additional intervention.

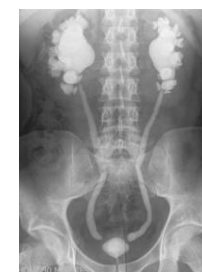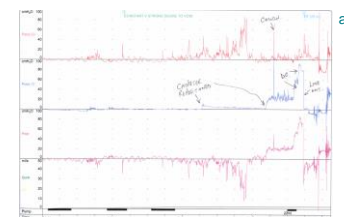
Surgical intervention	Total number of patients
substitution cystoplasty	6/13
augmentation cystoplasty	6/13
ileal conduit diversion	1/13
ureteric interposition using ileum	2/13
appendix Mitrofanoff formation	6/13

Post-operative complication	Total number of patients
urine leak	1/7
anastamotic leak	2/7
adhesional small bowel obstruction	1/7
wound necrosis	1/7
ureteric stricture	3/7
Mitrofanoff stenosis	1/7

## Conclusion

In a tertiary, high volume reconstructive unit we found ketamine patients seemed to be at particular risk of significant perioperative complications. There did not appear to be any other common factor apart from their use of ketamine, and the significant inflammatory change associated with this.

We recommend meticulous preoperative evaluation and multidisciplinary consultation for all patients to determine optimal treatment strategies.



**Figure 1**  
(a) Urodynamic trace of small capacity bladder with detrusor overactivity  
(b) CTU showing small capacity bladder with bilateral reflux