

## HIGH PREVALENCE OF BLADDER NECK OBSTRUCTION SUGGESTED IN PATIENTS WITH REFRACTORY CHRONIC PELVIC PAIN AND SMALL FIBER POLYNEUROPATHY

### Hypothesis / aims of study

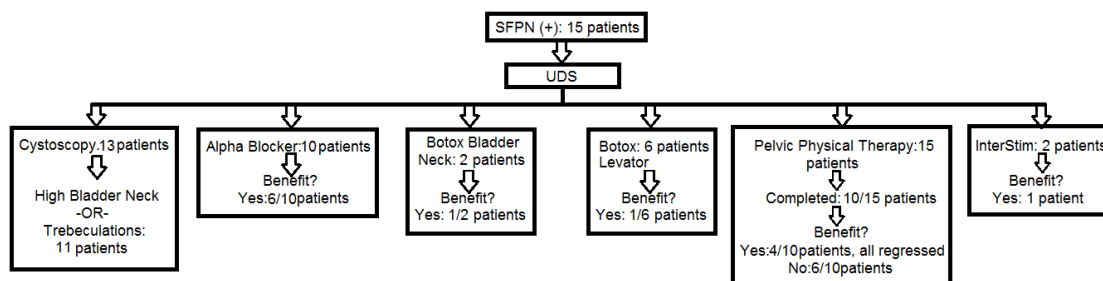
This study was designed to review the high incidence of bladder neck obstruction (BNO) observed clinically in patients with refractory chronic pelvic pain (CPP) and small fiber polyneuropathy (SFPN). SFPN can be evaluated based upon clinical presentation and skin biopsy findings and is defined as an overall decrease in epidermal nerve small fiber density as demonstrated on immunofluorescence analyses. Previous studies by our group suggest a dramatic increase in prevalence of SFPN in patients with refractory CPP and other comorbid pain syndromes such as irritable bowel syndrome (IBS) and fibromyalgia (FM) (64% versus published population data of 53/100,000 [2]). This suspicious co-occurrence supports the emergence of SFPN as an underlying etiology for multi-symptom syndromes involving chronic widespread pain. Identifying SFPN opens the opportunity for new systemic therapies for these patients (e.g. lidocaine infusion, IVIG). We have noted clinically a high prevalence of BNO in this population. We hope that phenotyping these patients with SFPN and BNO, will help direct local therapies for lower urinary tract symptoms (LUTS) in this traditionally difficult population with complex pain syndromes.

### Study design, materials and methods

In this retrospective chart review, we identified refractory female CPP patients seen in urology and neurology subspecialty referral clinics who were positive on biopsy for SFPN (3mm punch biopsies of the thigh and distal calf) and urodynamic testing. We chose to exclude two male patients and include only female patients since obstructive parameters are differentiated on the basis of gender. Tissue samples were sent to Corinthian Reference Lab (CRL). Control group was the normal cohort defined by CRL adjusted for age and gender. The sensitivity and specificity are 78-92% and 65-90% respectively. The different therapies that these patients tried, such as physiotherapy, alpha blockers, Onabotulinum toxin A, and InterStim therapy were queried and patient-reported outcomes were measured.

### Results

15 pts with refractory chronic pelvic pain had skin biopsies positive for SFPN and also underwent UDS. Of these patients, 9/15 or 60% demonstrated obstructive parameters referable to the bladder neck and the other 6 were unable to mount a detrusor contraction despite running water, privacy, and provocative fill on UDS. Average detrusor pressure at maximum flow  $p_{det}Q_{max}=31.3$ ,  $SD=13.2$  and average maximum flow rate  $Q_{max}=6.9$ ,  $SD=6.5$ . Cystoscopy was performed in 13/15 patients, in whom high BN or trabeculations were recorded in 11/13. 2 patients had a prior sling procedure which may have confounded UDS. Multimodal therapy was employed as follows. Alpha blockers were helpful in 6/10 patients who tried them. High tone pelvic floor dysfunction was present in all patients. All were referred to PT, 10/15 patients completed the course, 4/10 had some benefit but regressed, and the remaining 6 had <10% benefit in symptom relief. Onabotulinum toxin A to the levator muscles was performed in 6 patients with benefit in only 1. Onabotulinum toxin A to the bladder neck was administered in 2 patients, and benefitted 1. InterStim therapy was performed in 2 patients with benefit in 1 patient. Most patients are still under therapy and many have had interruptions in care due to missed appointments or awaiting outcome of care for the SFPN.



### Interpretation of results

Urodynamics were abnormal in all 15 patients. BNO was present on UDS in 9 patients, and absence of detrusor contraction with or without Valsalva to void were demonstrated in 6. The latter could indicate an atonic bladder or a manifestation of BNO, due to sympathetic stimulation of the bladder neck and suppression of the detrusor. The presence of a high bladder neck and/or trabeculations on cystoscopy in 11/13 patients corroborates the diagnosis of BOO. Of all of the treatments listed, alpha blockers were tried most often with an improvement rate of 57%. Although pelvic PT seemed to work at first and would not be discouraged in a multidisciplinary approach, all patients with SFPN regressed. Onabotulinum toxin A to the levators was only beneficial in 25% of patients. Botox to the bladder neck was tried in 2 patients, and was successful in one.

### Concluding message

In conclusion, patients with both refractory CPP and SFPN had a high incidence of urodynamic voiding dysfunction and BOO. Innervation of the bladder neck is a part of the autonomic nervous system and is thought to be sympathetic in nature. Sympatholytic agents such as alpha blockers and onabotulinum toxin A can decrease the tone at the bladder neck decreasing obstruction. Onabotulinum toxin A additionally inhibits the release of neurotransmitters related to the transmission of pain, such as calcitonin gene-related peptide (cGRP) and substance P, and acts as an analgesic, which can enhance the patient's perceived benefit [1]. Even though Onabotulinum toxin A injection to the bladder neck can be theoretically helpful, only one of the two

patients in this study who opted for it reported benefit. Although the exact role that the loss of small fibers plays has not yet been elucidated, this preliminary data shows that refractory pelvic pain patients with SFPN and LUTS should be evaluated for BNO. This condition should be treated as part of the multimodal approach to LUTS and pelvic pain in this patient population.

#### References

1. Argoff, C. E. (2003). "The Use of Botulinum Toxins for Chronic Pain and Headaches." *Curr Treat Options Neurol* 5(6): 483-492.
2. Peters M. J., et al. (2013). "Incidence and prevalence of small-fiber neuropathy: a survey in the Netherlands." *Neurology* 81: 1356–1360.

#### Disclosures

**Funding:** NONE **Clinical Trial:** No **Subjects:** HUMAN **Ethics Committee:** Albany Medical Center Institutional Review Board  
**Helsinki:** Yes **Informed Consent:** Yes