



#405 Overactive bladder “de novo” after surgery - ultrasonographic tape localisation as a useful diagnostic tool – a preliminary report.

Pawlaczyk A, Matuszewski M.

Urological Department, Medical University of Gdańsk, Poland

Hypothesis / aims of study

Surgical treatment of stress urinary incontinence in women with the use of polypropylene tape has become a standard procedure. One of the complications observed postoperatively is overactive bladder (OAB) “de novo” and it may occur among even 42% of patients.

The aim of this observational retrospective case-control study was to determine the correlation between the sonographic appearance of the tape in relation to the urethra and the occurrence of OAB “de novo” after surgical treatment.

Study design, materials and methods

A group of 26 patients suffering from OAB “de novo” after surgical treatment for stress urinary incontinence using polypropylene tension free vaginal tape was included in this study. The assessment consisted of medical history, uroflowmetry with residual volume, urogynecological examination, and introital and transvaginal sonography. Translated questionnaires (UDI6, Sandvik, IIQ7) were also completed. The patients with pelvic relaxation syndrome, acute postoperative urinary retention, implants erosion, urinary tract infection, OAB before surgery or persistent stress urinary incontinence were not included in this study. The control group consisted of 40 patients after the same treatment without any complications and with a good outcome. Tape visualisation was performed at rest in midesagittal and transverse plane using introital and transvaginal two – dimensional ultrasonography. There were three parameters measured, which specified the tape position. On the midesagittal scan we have measured the distance between the external urethral orifice and the lower edge of the tape and the urethral length. On the transverse scan we have measured the distance between the tape and the lumen of the urethra. Differences were statistically tested using a chi-square test.

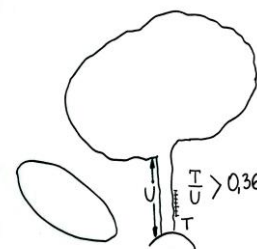
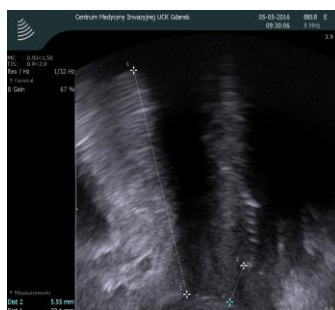

Figure 1: Tape visualisation in midesagittal plane.

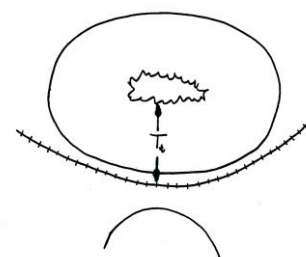
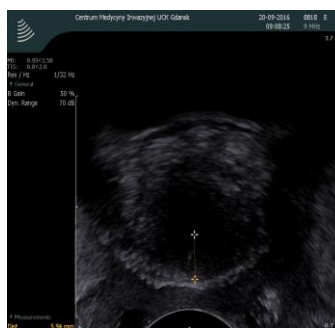

Figure 2: Tape visualisation in transverse plane.

Results

In the group of patients suffering from OAB “de novo” postoperatively, the implant was located more often under the proximal part of the urethra in comparison to the control group (Chi-square test = 11,74; p<0,001) and this was statistically significant. The distance between the tape and the lumen of the urethra, measured in the transversal plane at rest, had no correlation with the occurrence of OAB “de novo” after surgery (Chi-Square test =0,31; p=0,6).

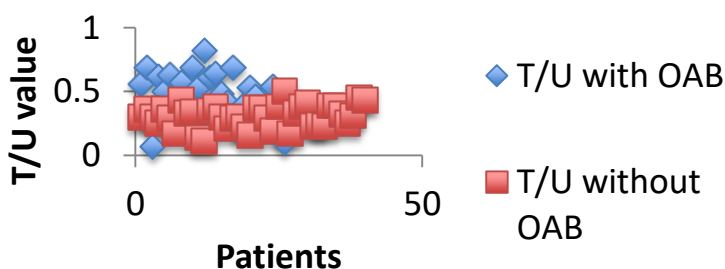


Table 1: Patient characteristics, average values.

Nr of pts	TOT	TVT	Age (on the day of OP) years	BMI (on the day of OP)	Time (from the OP to the date of control)	Vres	UDI 6	T/U	Frequency (0-3)	Urgency (0-3)
26 (OAB)	9 (35%)	17 (65%)	60,1	28,8	4 years	65 ml	8,5	0,47	2,54	2,88
40 (control group)	0 (0%)	40 (100%)	58,25	28,03	0,5 year	4 ml	0,73	0,31	0,2	0,075

Interpretation of results

The tape position in the proximal urethra may have an impact on the postoperative occurrence of OAB “de novo”. The distance between the tape and the urethral lumen measured in the transversal plane had no impact on the occurrence of OAB “de novo”.

Concluding message

Special care of the tape fixation should be considered to prevent dislocation of the tape. This simple method of ultrasonographic examination allows the identification of patients at risk for the development of OAB “de novo” after sling procedure.