

# Low bladder capacity is an important predictor for comorbidity of interstitial cystitis with Hunner's lesion in patients with refractory chronic prostatitis/chronic pelvic pain syndrome (CP/CPPS)



Masakatsu Ueda<sup>1</sup>, Tomohiro Ueda<sup>2</sup>, Atsushi Sengiku<sup>1</sup>, Naoki Yoshimura<sup>3</sup>, Ryoichi Saito<sup>1</sup>, Hiromitsu Negoro<sup>1</sup>, Osamu Ogawa<sup>1</sup>

1. Kyoto University 2. Ueda Urology Clinic 3. University of Pittsburgh

## Hypothesis / aims of study

- The association between interstitial cystitis (IC) and CP/CPPS has not been well studied.
- We have previously reported that cystoscopy assisted with narrow band imaging (NBI) is useful for the diagnosis of IC/BPS.
- This study aims to evaluate the predictive factor for comorbidity of Hunner-type IC in CP/CPPS patients using NBI-assisted flexible cystoscopy.

## Study design, materials and methods

- 32 male patients were retrospectively examined. They were diagnosed with CP/CPPS according to the NIH classification at Ueda Urology Clinic from April 2012 to April 2016 and their symptoms were not improved by 3 months of behavioral and pharmacological therapies including  $\alpha 1$ -adrenoceptor blockers.
- In all the patients, the National Institute of Health Chronic Prostatitis Symptom Index was assessed, followed by urethroscopy with NBI under local anesthesia with 4% lidocaine.
- We evaluated whether the presence of Hunner's lesions is associated with other variables such as age, symptom scores, maximal voided volume per micturition, maximal bladder capacity during cystoscopy and the presence of inflammatory polyps at the prostatic urethra.

## Results

- The mean age of the patients was 59.1 (range: 23-84).
- The mean total score of the NIH-CPSI was 22.8, and pain, urinary, and quality of life subscores were 9.7, 5.1, and 8.1, respectively.
- 13 patients (41%) had Hunner's lesions and 15 patients (47%) had urethral polyps. Representative findings are shown in Figure 1-3.
- Maximal voided volume and bladder capacity were significantly smaller, and the prevalence of prostatic urethral polyps (30.8% vs 57.9%) was not significantly different in patients with Hunner's lesions compared to those without. Other variables except age were not significantly different (Table 1).
- Patients with voided volume below 150 ml were more likely to have Hunner's lesions than those with voided volume of 150 ml or more with sensitivity and specificity of 100% (13/13) and 63.2% (12/19), respectively.

Figure 1. Bladder mucosa under conventional cystoscopy. (A) whitish and folded mucosa of a non-IC patient (shown as a control) (B) hypervascular mucosa of a 31-year-old male IC patient

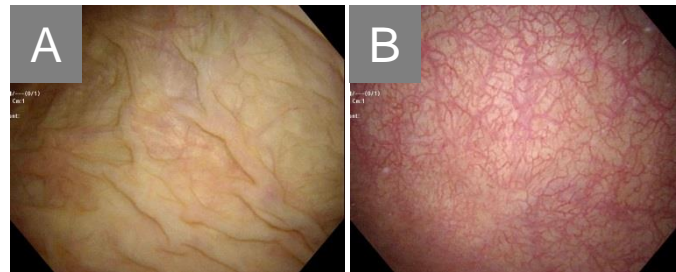


Figure 2. A Hunner's lesion (arrow) in a 69-year-old male patient with (A) white light and (B) NBI. The NBI system facilitates appropriate evaluation of Hunner's lesions.

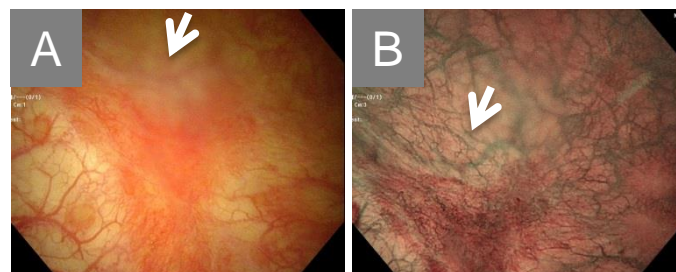
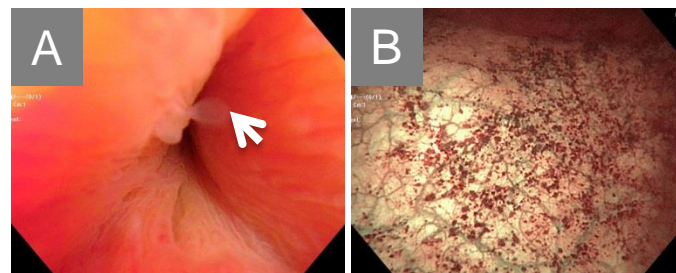


Figure 3. Other remarkable findings. (A) a polyp at the prostatic urethra of a 43-year-old male patient (B) glomerulation after distention in a 24-year-old male patient



## Interpretation of results

- Hunner-type IC seems to be a common comorbidity in patients with refractory CP/CPPS, especially when their maximal voided volume is less than 150ml. Their small bladder capacity may partly be explained by the existence of Hunner's lesions.
- Prostatic urethral polyp is also a prevalent finding in those patients. Further investigations are needed to elucidate whether there is any association between Hunner's lesions and urethral polyps.

	Hunner's lesion(+) n=13	Hunner's lesion(-) n=19	P value
Age	67.3	51.6	0.0253
Total score	22.2	23.6	0.687
Pain subscale	8.9	10.7	0.3894
Urinary subscale	5.5	4.6	0.4398
QOL subscale	7.7	8.4	0.4944
Bladder capacity (ml)	268.5	406.8	0.0061
Voided volume (ml)	106.2	170.5	0.0004

Table 1. Comparison of the patients' characteristics between those with Hunner's lesions and those without

Disclosures: Nothing  
Funding: Self-funded

## Conclusion

In refractory CP/CPPS patients whose voided volume is small, performing NBI-assisted urethroscopy should be taken into consideration for the reliable diagnosis of bladder and urethral mucosal changes such as Hunner's lesions.