

693

Shibata C<sup>1</sup>, Ishii T<sup>2</sup>, Kanya K<sup>3</sup>, Mayuko K<sup>3</sup>, Miki F<sup>4</sup>, Oikawa S<sup>5</sup>, Hlshinuma A<sup>5</sup>, Sakakibara R<sup>6</sup>, Yamanishi T<sup>3</sup>, Igarashi T<sup>2</sup>

1. Continece Center / Laboratory Center, Dokkyo Medical University Hospital, Division of Artificial Systems Science, Graduate School and Faculty of Engineering, Chiba University, 2. Center for Frontier Medical Engineering, Chiba University, 3. Continece Center, Dokkyo Medical University Hospital, 4. Continece Center, Dokkyo Medical University Hospital, 5. Laboratory Center, Dokkyo Medical University Hospital, 6. Department of Neurology, Toho University, Sakura Medical Center

## THE MORPHOLOGICAL CHARACTERISTICS OF THE BLADDER CONTRACTION IN FEMALE

### Hypothesis / aims of study

We aimed to assess the bladder contraction patterns in female by contour extraction and tracking using fluoroscopic image sequences.

### Study design, materials and methods

We retrospectively identified 9 female patients who underwent videourodynamics at sitting position, according to ICS standards, in 2012 - 2013: mean age 56 – 73 years old, being normal observations. We extracted the bladder contour from X-ray fluoroscopic images during voiding using active contour method. Each pixel coordinate on the extracted contour was projected into a polar coordinate system, which expresses a distance from the centroid of bladder and an angle from the sagittal plane. The wave form of the projected points (graph) was defined as the morphological character of the bladder. We analysed the patterns and amount of the change of the graph at the time of permit to void (PV), onset of flow (OF), maximum flow rate (Qmax), end of flow (EF), maximum detrusor pressure (PdetQmax).

### Results

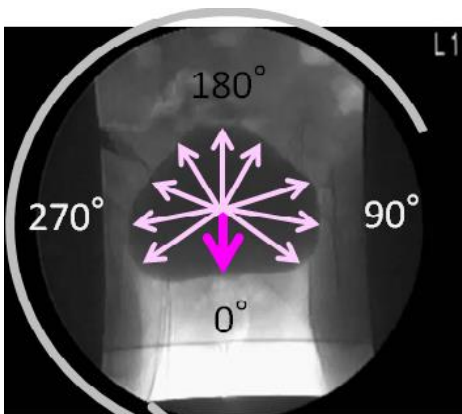
The shape of bladder could be clustered into four patterns by the shape of wave form, two bimodal convex type, one bimodal concave type, four tri-modal convex type, two multimodal type were observed at the time of PV. During PV and OF, change of the morphological pattern became maximum in the voiding phase for most cases. The distance from the centroid around zero degree became long in five females, and the distance from the centroid around 290 degrees and 50-60 degrees became short in three females. The distance from the centroid around zero degree became long in all three females whose post void residual urine (PVR) was less than 50mL.

### Interpretation of results

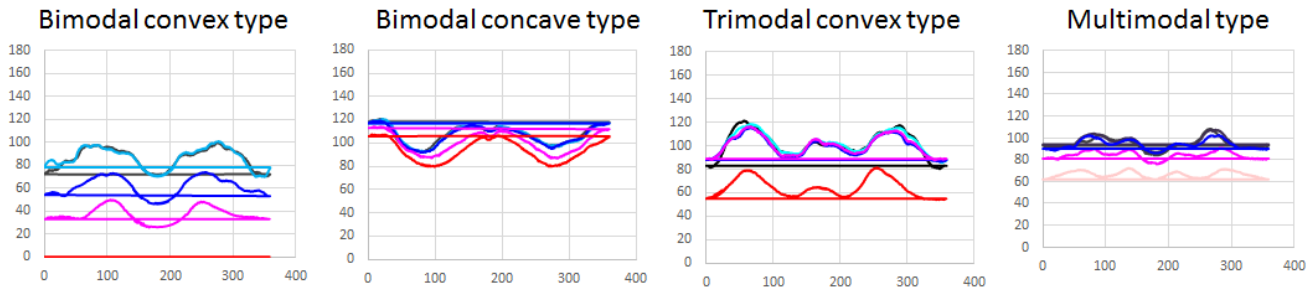
This is the first study to visualise bladder motion using videourodynamics (X-ray images) by an image contour extraction method. Previously, the bladder neck opening described as that preceded voiding. Similarly, this study showed by videourodynamics and contour extraction method, that bladder neck open prior to voiding. Since bladder neck and bladder base motion were recorded before voiding, the motion may be come from urethral longitudinal smooth muscle. In latter half of voiding, the bladder contour tended to become small concentrically. In addition, the graph-based bladder shape analysis might be useful to assess the bladder deformation and contraction.

### Concluding message

We showed that the change of bladder motion derived the graph using centroid of bladder contour by videourodynamics and contour extraction method. Since bladder neck and bladder base motion were recorded before voiding, the motion might be come from urethral longitudinal smooth muscle. This morphological analysis of bladder contraction may be beneficial to evaluate local detrusor motion and voiding function.



bladder contour and the way to make graph



The patterns of bladder contour graph

**References**

1. Hirahara N, Ukimura O, Ushijima S, Yamada Y, Okihara K, Kawauchi A, Miki T. Four-dimensional ultrasonography for dynamic bladder shape visualization and analysis during voiding. *J Ultrasound Med.* 2006 Mar;25(3):307-13.
2. Chan TF, Vese LA. Active contours without edges. *IEEE Trans Image Process.* 2001;10(2):266-77

**Disclosures**

**Funding:** no **Clinical Trial:** Yes **Public Registry:** No **RCT:** No **Subjects:** HUMAN **Ethics Committee:** Dokkyo Medical University Hospital Ethics Committee **Helsinki:** Yes **Informed Consent:** Yes