

3D printed real-time Sacral bone model for proper electrode implantation in sacral neuromodulation:

A new technique for lead placement

Culha MG¹, Onur R², Otunctemur A¹, Altunrende F¹

1. University of Health Sciences, Okmeydanı Training & Research Hospital,

2. Marmara University



ABSTRACT

The purpose of this study is to develop a model that will contribute to the learning curve of sacral neuromodulation (SNM) learning and to make the process more effective and easy to implement and the details of this method and the creation of a three dimensional (3D) sacral bone model are presented.

METHODS

A 49-year-old woman with complaints of increased urinary frequency (frequency) and pelvic pain for seven years applied to the urology polyclinic.. Previously, there was no improvement in the patient with interstitial cystitis diagnosis and treatment with 3 different anticholinergic agents for 1 year, oral pentosan polysulfate, intradetrusor botulinum toxin injection for 3 years, and intravesical hyaluronic acid treatment for 1 year. With the bladder diary, it was determined that the maximum capacity was 100cc, the urine frequency / day was 23-24 times and the average interval between the micturition was 20 minutes.

RESULTS

A 3D sacral bone model was created for the patient to facilitate the procedure and to explain it easily. For this procedure, first, thin-section computed tomography was taken in the sacral region of the patient. 489 axial DICOM files with 1.5 mm cross-sectional thickness were obtained. This data set was converted into axial, sagittal and coronal sections using the open source InVesalius (Ver. 3.0) program. The appropriate threshold value was determined on the axial, sagittal and coronal sections to determine the desired region of the patient, and the corresponding 3-dimensional model was created. After the model was created and the artefacts were cleaned, the model which will printed from the 3D printer was formed and prepared to be printed. (Figure 1). Then, with the help of the 3D model program, the whole process of the patient was explained in detail. It was decided to apply sacral neuromodulation to the patient after interview with the patient, visual expression and informed consent. Through the 3D model, the distance between the skin and the foramen, the entrance angle, the number of foramen, the double sided localizations, the sacral interior cut were observed in detail and the needle entry simulation was performed on the 3D model. Under general anesthesia, after induction, the sacral foraminae were localized in the prone position by X-ray imaging. The distance between the skin and the foramen and the entrance angle were calculated (skin-foramen distance: 7.12 cm, entrance angle: 68 degrees). The midline length of the S3 foraminae was calculated with the aid of the 3D model (1.5 cm on the right, 1.8 cm on the left, Fig. 1a-d). Needle entry was made with more precise and correct angle because these distances were known. Confirmed with simultaneous fluoroscopy. (Medtronic® 3550-18 Introducer kit, Minneapolis, MN, USA). Test stimulation was performed and the patient's sensory response was monitored. After the ideal stimulation response was determined, the guidewire was placed through the test needle. Then it was implanted with the help of a Medtronic 3889-41 (Minneapolis, MN, USA) Tined lead scopy. During this process, the scoping time was calculated as 18 seconds. One month after the procedure, it was observed that the number of micturitions decreased to 12 a day and the duration between the micturitions was about 120 minutes. The patient then was implemented Medtronic 3058 Interstim II (Neurostimulator) permanent device under local anesthesia.

INTERPRETATION OF RESULTS

The success of the SNM treatment depends on the continuous electrical stimulation in S3 foramen, appropriate patient selection, introduction towards the S3 foramen, and electrode placement in the appropriate position. Percutaneous electrode implantation and trans-foramen implantation have relative learning curves in centers where the procedure is not frequently applied. The SNM procedure performed with the assistance of 3D sacral bone model, which is presented as a new technique, has helped to achieve better results for both the patient and the practitioner. Further studies with larger patient population are needed for the development of this model.

CONCLUSIONS

Success of sacral neuromodulation (SNM) treatment depends on S3 foramendous continuous electrical stimulation, appropriate patient selection and S3 foramen correct entry and placement of the electrode in the appropriate position. Percutaneous electrode implantation and trans-foramen implantation are a relatively straightforward learning curve in centers where they are not frequently used. As a new technique, the SNM operation with the aid of the 3D sacral bone model has helped to achieve better results for both the patient and the practitioner. There is a need for larger series of studies to develop this model.

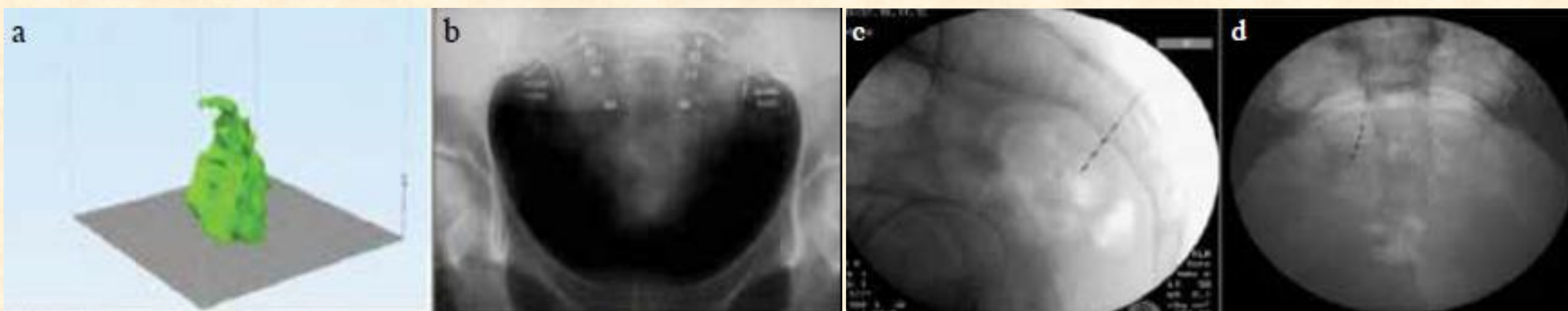


Figure 1. a-d. 3D sacral bone model obtained by the patient's CT images (a). X-ray determination of sacral foramen (b). The electrode placement to S3 foramen (c). Insertion of electrode into S3 foramen (d)

REFERENCES

Funding None. Clinical Trial Yes Public Registry No RCT No Subjects Human Ethics Committee 981/2018 Helsinki Yes Informed Consent Yes