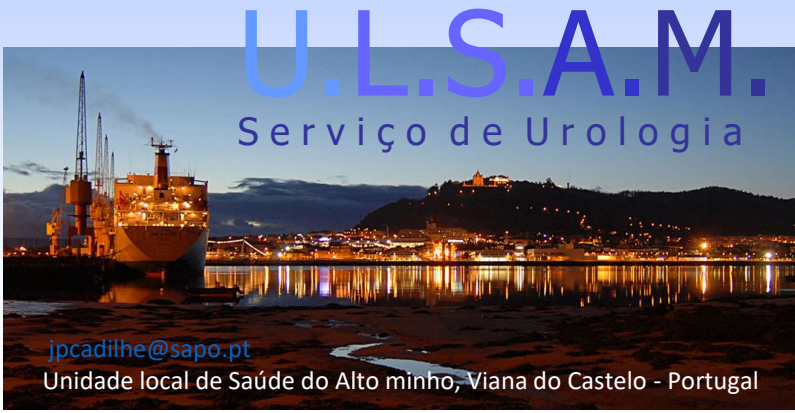

# #128 A retrospective long-term study of synthetic slings erosion in the transobturator “outside-in” approach with a single type of mesh.



José Pedro Cadilhe<sup>1</sup>, José Leitão<sup>2</sup>, Hugo Coelho<sup>2</sup>, Eurico Maia<sup>2</sup>

1 - MD, FEBU - ULSAM, Viana do Castelo & Universidade do Minho, Braga – PORTUGAL  
2- MD- ULSAM, Viana do Castelo & Universidade do Minho, Braga - PORTUGAL

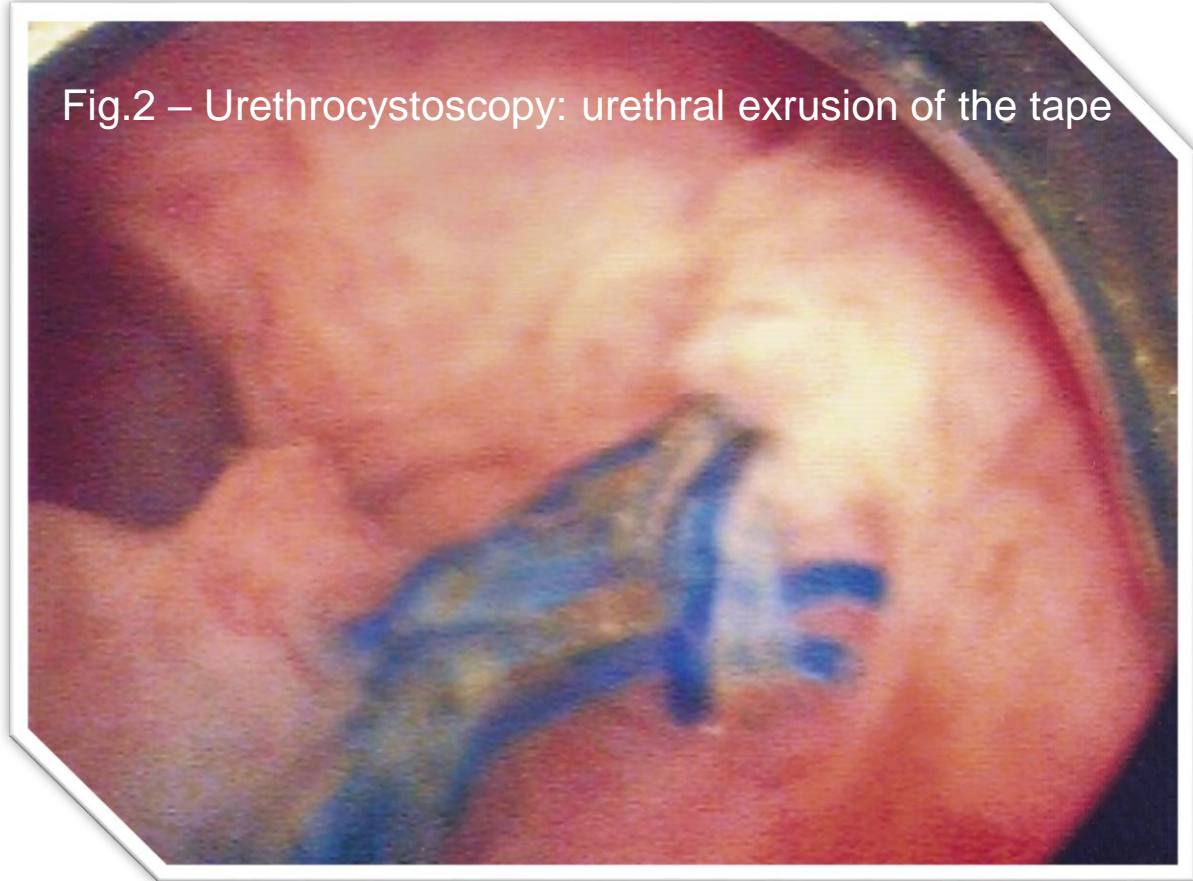



## Introduction

Midurethral tapes, currently the standard of care in the management of urodynamic stress incontinence (USI), are associated with a risk of erosion and extrusion of the synthetic material into the vagina and urethra, turning it into a major concern. The reported rates of intravaginal erosion of suburethral slings range up to 13.8% [1]. The rates are higher with nonknitted polypropylene tapes as compared to knitted macroporous monofilament Type I tapes (<5%) [1]. A review assessing effectiveness and complications of TOT vs TVT, showed that vaginal injuries or erosion of the mesh (OR 1.96; 95% CI 0.87-4.39) were more common after tape insertion by transobturator route [2]. On the other hand, the incidence of intraoperative complications is thought to be independent from the type and characteristic of the mesh used, and directly related to the route of insertion of the needle and surgeon's experience. The purpose of this study was to evaluate the feasibility and the safety of the TOT procedure with this particular SERASIS® Tape, as well as documenting the post-operative long term sling erosion / extrusion.

## Methods

We retrospectively evaluated 848 patients who underwent the transobturator procedure using SERASIS® systems by the same surgeon between 2006 and 2019 (SERASIS® MR tape: non elastic, softly knitted monofilament blue non-absorbable polypropylene, Serag-Wiessner, Naila, Germany) (Fig. 1.1) for the cure of USI, and required surgical review for tape problems. The SERASIS® trocar sets designed for specific purposes can be used depending on the surgeon's preferences and the anatomical conditions presented by the patient (e.g. SERASIS® TO, XXL, SL) (Fig1.2). When vaginal erosion occurs, the patient usually manifests persistent vaginal discharge, vaginal bleeding, postcoital bleeding, and pain during intercourse or male partner discomfort. Diagnosis was confirmed by visual inspection or palpation of the tape in the vagina. Care must be taken to exclude urethral and bladder erosions, as such we performed Urethrocystoscopy whenever dysuria or UTIs appear (Fig. 2).



## Results

The rate of erosion in our series was slightly less than 0,5% (4/848). Almost all of the patients developed the erosions within a few months (5 -16 months) after an apparently uncomplicated surgery thus being treated with partial removal of the eroded sling (Fig.3). Only one had urethral and vaginal extrusion corrected 8 years after the procedure. We also report 0,6% patients (5/848) who underwent urethrolisis with tape section due to obstructive voiding complaints. All 4 patients remained with social continent after removal of the sling (the patient with vaginal and urethral extrusion became worse), as well as those 5 submitted to the tape section.

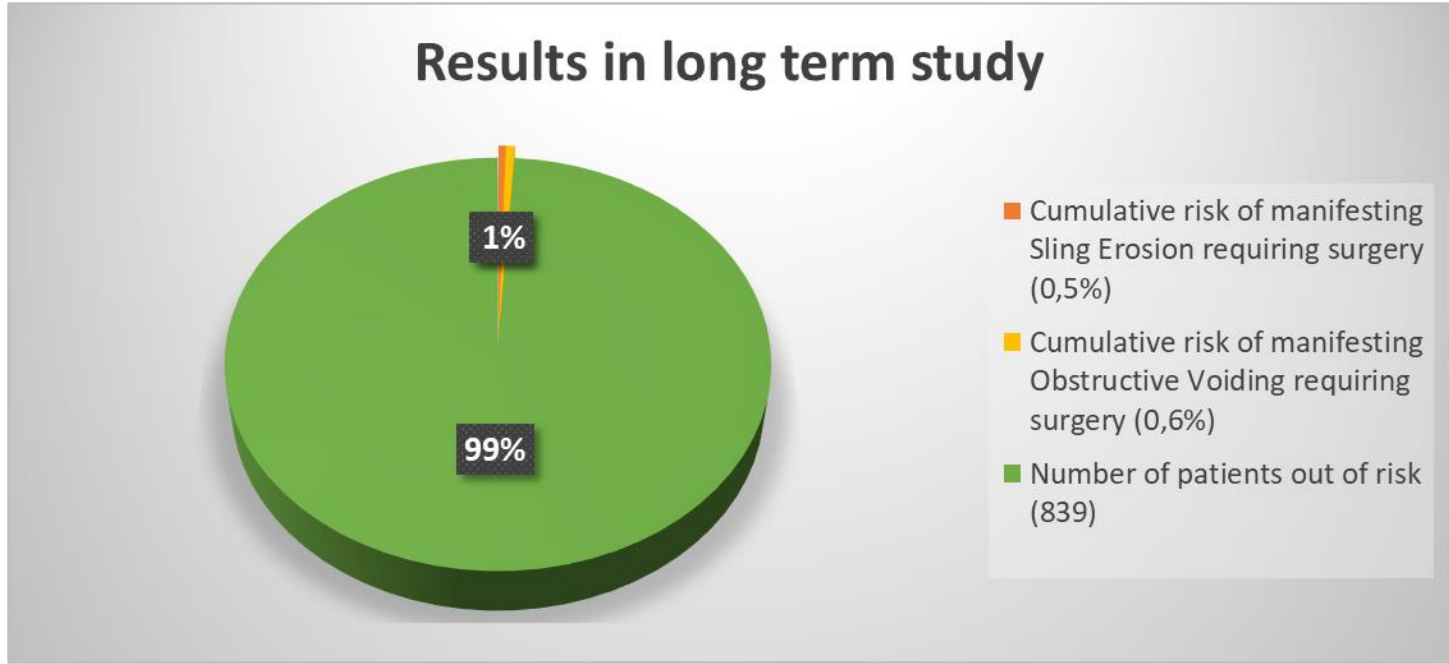
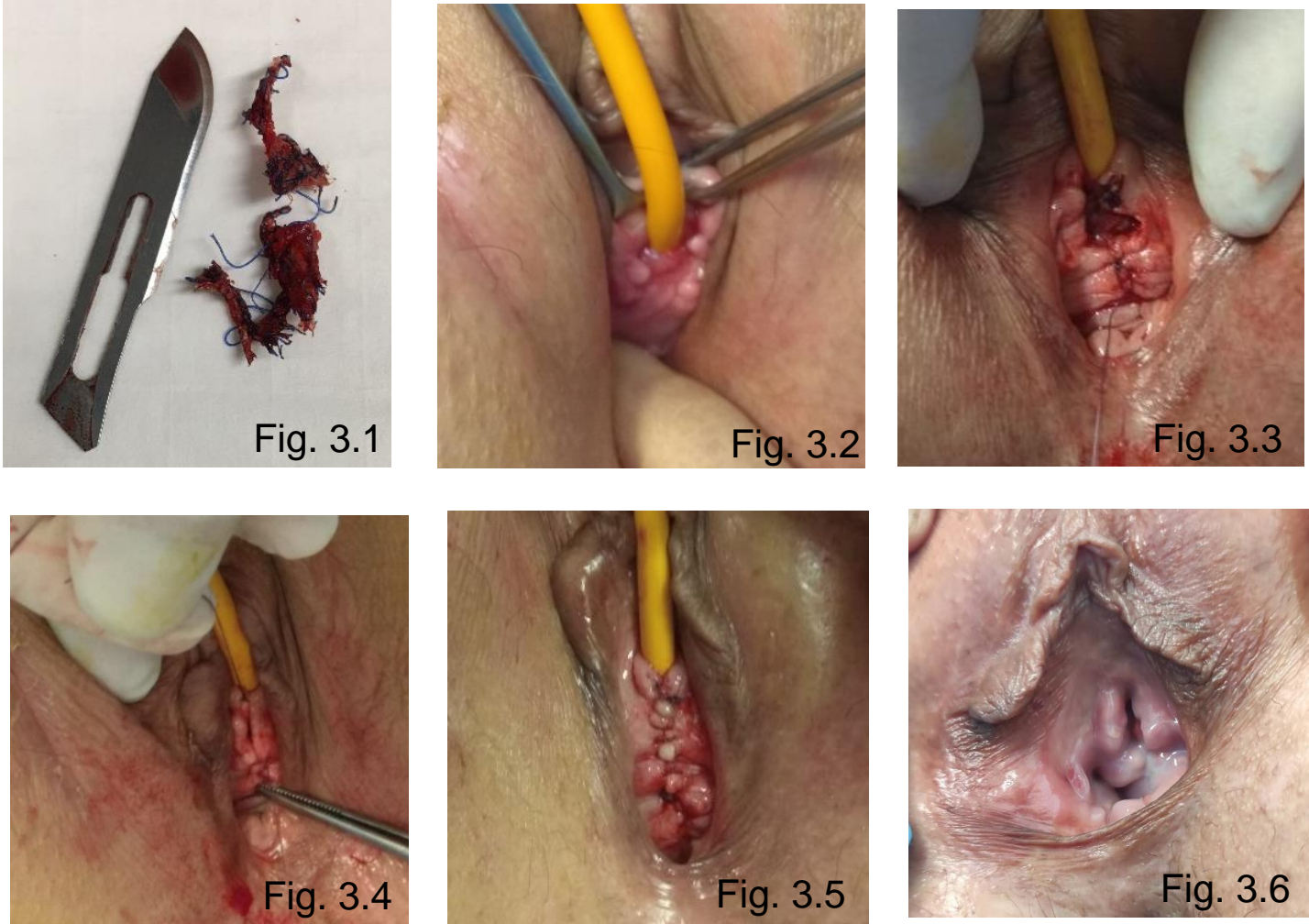


Fig.3 - parcial removal of the eroded sling with second stage urethroplasty.



**Interpretation of results:** Complications and malfunctioning after TOT can occur due to several factors, with one of those being the material of the sling. The present cohort highlights the importance of the long-term follow up after any sling procedure as erosion and/or extrusion may arise at any time following the procedure. We believe that the favorable results of this study might help surgeons to be more accurate when choosing Tapes.

## Conclusions

The authors of this study conclude that using SERASIS® MR, a softly knitted monofilament non-absorbable polypropylene tape, might result in lower pain levels in short and long terms post-operative course, as well as reduced tape extrusion to the vaginal cavity or to the urethra.

## References

[1] Sivanesan K, Abdel-Fattah M, Tierney J. Perineal cellulitis and persistent vaginal erosion after transobturator tape (Obtape)—case report and review of the literature. International Urogynecology Journal. 2007;18(2):219–221.

[2] Latthe PM, Foon R, Tooze-Hobson P (2007) Transobturator and retropubic tape procedures in stress urinary incontinence: a systematic review and meta-analysis of effectiveness and complications. BJOG 114(5):522–531