

ROLE OF PELVIC FLOOR ULTRASOUND IN THE FOLLOW-UP OF PATIENTS WITH MID-URETHRAL SLINGS.

Introduction

Up to 5-20% of mid-urethral slings (MUS) will fail causing persistence or recurrence of stress urinary incontinence (SUI), with the estimated incidence of reintervention following MUS placement being around 6% in the following 5 years after surgery.

One of the causes of MUS failure could be an inadequate surgical implantation technique. Misplacement of the MUS can be verified by pelvic floor ultrasound (PF-US), checking the adequate sling position, symmetry, sling distance to the urethral lumen and the concordant movement between the sling and the urethra during Valsalva maneuver.

The **aim of this study** was to evaluate the role of PF-US in explaining surgical failure in patients with persistent or recurrent urinary incontinence symptoms after MUS surgery for SUI at mid-term follow-up.

Methods and Materials

We carried out a historical cohort study including women undergoing MUS surgery for SUI with transobturator MUS (TOT-MUS) and retropubic MUS (RT-MUS) between 2013 and 2015 in a tertiary university hospital. The inclusion criteria were women who underwent SUI surgery with a TOT-MUS or a RT-MUS and accepted to attend to a face-to-face control visit five years post-surgery. The face-to-face visits were performed between September 2019 and March 2020.

Preoperatively, all patients were assessed using the Spanish-validated questionnaire *Incontinence Questionnaire-Short Form* (ICIQ-UI-SF), a pelvic examination and an International Continence Society (ICS) standard urodynamic test (ICS-SUT).

At the five-year post-surgery visit, patients were assessed using the ICIQ-UI-SF, a pelvic examination, an ICS Uniform Cough Stress Test (ICS-UCST), a urethral pressure profile, an uroflowmetry and a PF-US. With the PF-US we evaluated the sonographic parameters of the MUS which included its position relative to the urethra, the distance to the urethral lumen (in *mm*), the symmetry and the concordance of the urethral movement with the MUS during the Valsalva. The movement was considered concordant when the sling location on maximal Valsalva relative to the urethral length was identical to that at rest, causing urethral kinking.

The primary outcome of the study was the correlation of MUS's sonographic parameters with SUI cure (negative ICS-UCST, ICIQ-UI-SF <5 points and no symptoms of SUI), at five-years post-surgery. Secondary outcomes were the changes at 1 and 5 years after surgery of maximum urethral closure pressure (MUCP) and the presence of symptoms of urgency urinary incontinence (UUI).

Results

Eighty-seven patients (80 TOT-MUS, 7 RT-MUS) were included. The mean age of patients was 56.8 years and 61% of women were menopausal. The mean number of vaginal deliveries was 1.9 and the mean body mass index was 28.1 Kg/m². The mean score of ICIQ-UI-SF was 16.0 points with 57% of patients explaining UUI symptoms, and the mean MUCP was 61.9 cmH₂O.

Five years after surgery, all patients explained improvement of urinary incontinence and objective cure of SUI was demonstrated in 81.2%. According with the answers of the ICIQ-UI-SF, when this preoperative proportion of patients with UUI was compared with the postoperative proportion at five-year follow-up, no significant difference was found (p=0.560).

The MUS was sonographically correct in 67 (98.5%) of the 68 patients with cure of SUI. In only 4 (28.6%) of the 14 patients with non-cured SUI, the MUS was considered incorrectly placed (Table 1).

The MUCP decreased from 61.9 to 48.8 cmH₂O at 5 years follow-up (p<0.01) and up to 53% of women had UUI symptoms after surgery, with a non-significant decrease compared to baseline.

Table 1. Distribution of stress urinary incontinence curation according to sonographic MUS assessment (correct and incorrect) at five years of follow-up. N=82 (patients with excision of the MUS were excluded from this analysis).

Curation of SUI; n (%)				
		No	Yes	Total
SONOGRAPHIC MUS ASSESSMENT; n (%)	Incorrect	4 (4.9)	1 (1.2)	5 (6.1)
	Correct	10 (12.2)	67 (81.7)	77 (93.9)
	Total	14 (17.1)	68 (82.9)	82 (100)

SUI: stress urinary incontinence, MUS: mid-urethral sling.

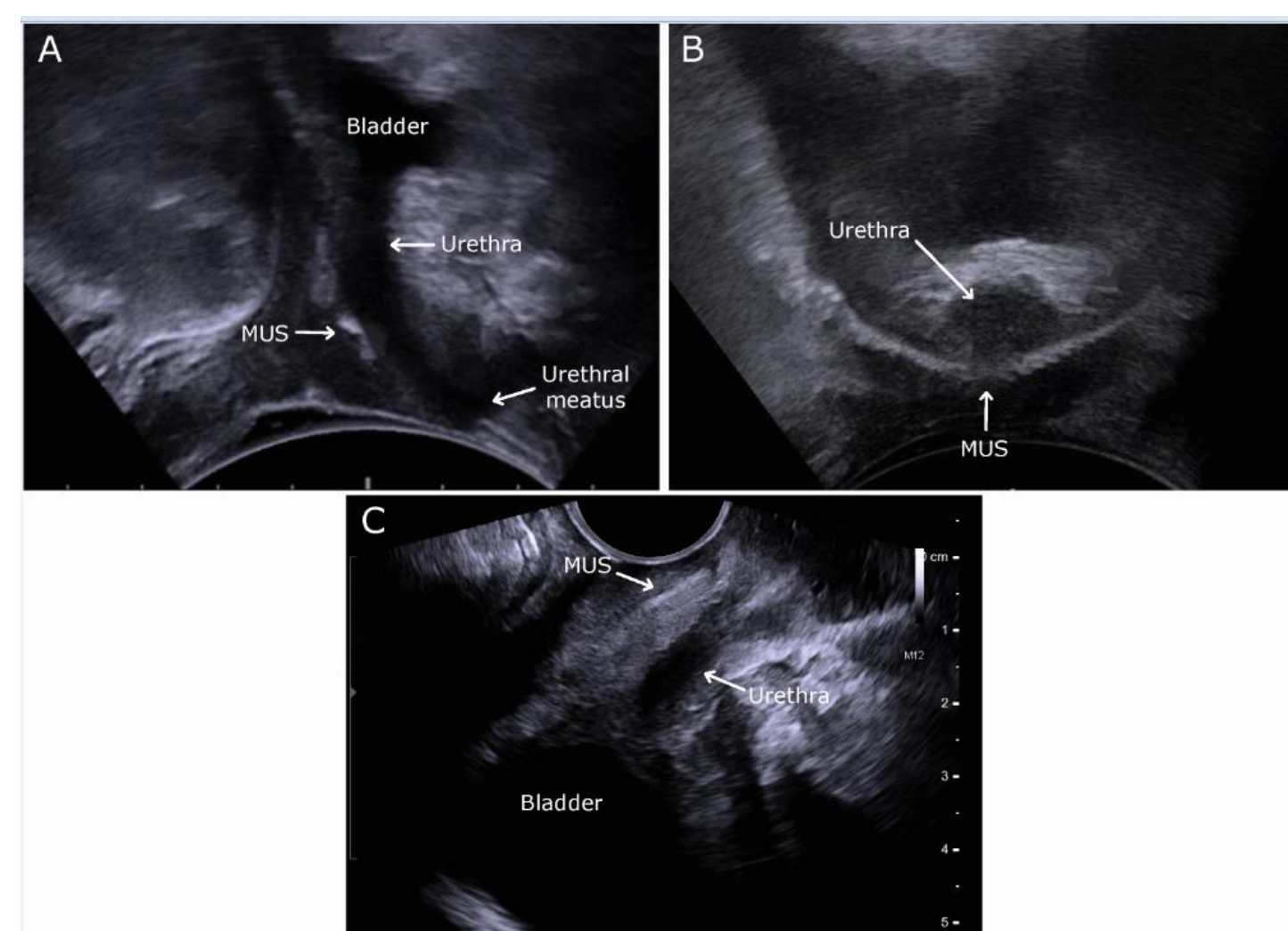


Figure 1. Sonographic assessment of a correct MUS. A: Mid-sagittal plane obtained by transperineal ultrasound at rest with a convex probe (type 8802, Fleshfocus 400, BK Medical). B: Transverse plane obtained by transperineal ultrasound at rest with a convex probe (type 8802, Fleshfocus 400, BK Medical). C: Mid-sagittal plane obtained by transvaginal ultrasound at rest by endovaginal probe (type 8819, Fleshfocus 400, BK Medical). MUS: mid-urethral sling.

Conclusions

Patients cured of SUI showed sonographically correct MUS placement by PF-US.

In a specialized urogynecological center, less than one third of cases of SUI persistence or recurrence after MUS surgery could be explained by a sonographically incorrect sling.

Low urethral resistance and/or UUI symptoms could help explaining the remaining failures.

In patients with SUI persistence or recurrence after MUS, a complete functional and anatomic study, including urodynamics and PF-US, may be useful before deciding on the next management strategy.