

#588 Impactful Complication after Prostate Cancer Treatment: Urological Fistula with or without Osteomyelitis of the Pubic Symphysis

A.A. Pronk, R.P. Meijer, L.M.O. de Kort, M.I.A. Wyndaele

University Medical Center Utrecht, The Netherlands



Introduction

Prostate cancer (PCa) is the second most commonly diagnosed cancer in the world. Primary treatment options include radiation therapy (external beam or brachytherapy) and radical prostatectomy (with or without pelvic lymph node dissection). The survival rate for men with prostate cancer is high and life expectancy after primary treatment is increasing.

PCa treatment, while effective, can lead to severe complications like urological fistulas and osteomyelitis of the pubic symphysis. Little is known about the prevalence of this rare complication. After recovering from PCa, a fistula and/or osteomyelitis can have a significant negative impact on general health and quality of life.

The past decade, a rapidly increasing number of patients with fistula and/or osteomyelitis after PCA treatment presented in our institution. This retrospective study describes an overview of these patients.

Methods

- Evaluated patients (2014-2023) attending our tertiary referral center with urological fistulas after PCa.
- Classified fistulas as recto-vesical (RVF), urethro-cutaneous (UCF), or urosymphyseal (USF).
- Examined patient characteristics, treatment histories, and presenting symptoms.
- Analyzed surgical approaches, specialists involved, and outcomes.

Results

- 18 patients studied: 12 referred from other hospitals.
- Symptoms included pain, mobility loss, incontinence, infections, and urosepsis.
- 13 USF, 4 RVF and 1 UCF cases identified.
- RVF occurred often immediately after PCa treatment and USF occurred years later (mean 9 years).
- Focusing on USF: 85% of patients had prior radiotherapy more than 5 years ago, and additionally 62% received a endourological treatment (88% of those ≥ 2 procedures).
- Multidisciplinary teams managed 83% of cases.
- Median length of hospital stay was 17 days (range 3 – 41).

Conclusion

- Different disease courses observed for RVF and USF.
- RVF developed immediately after treatment of PCA.
- USF developed after many years after PCa treatment and often shortly after endourological treatment in previously irradiated patients.
- Surgical treatment of urological fistula should be performed in a center of expertise by a multidisciplinary team.

Table 1. Characteristics and specifications of surgical treatment of patients treated for urological fistula and/or osteomyelitis after PCa therapy

Patiënts with fistula and/or osteomyelitis	N = 18
Age (years, SD)	76 ± 5
ASA classification	3 (2-4)
Fistula	
- Urosymphyseal	13 (72%)
- Rectovesical	4 (22%)
- Urethrocutaneous	1 (6%)
Osteomyelitis	14/18 (74%)
- Urosymphyseal fistula	13/13 (100%)
- Rectovesical fistula	1/4 (25%)
- Urethrocutaneous fistula	0/1 (0%)
Primary PCa treatment	
- Radical prostatectomy	12 (67%)
- Radiotherapy	6 (33%)
o External	5
o Brachytherapy	1
Secondary PCa radiotherapy after prostatectomy	10/12 (83%)
- Adjuvant radiotherapy	3
- Salvage radiotherapy	7
Endoscopic dilatation or incision VUAS or resection of the prostatic urethra	11 (61%)
- 1 procedure	1
- ≥ 2 procedures	10
Surgical treatment for fistula and/or osteomyelitis	15 (83%)
Specifications procedure	
- Cystoprostatectomy	13
o Ileal conduit	11
o Colon conduit (colon shuffle)	2
- Symphysectomy	8
- Rectus flap	9
- Omentoplasty	4
- Rectovesical fistula repair	2
Duration of surgery (minutes, SD)	370 ± 77
Complications (Clavien-Dindo classification ≥ 3)	4 (21%)
Score 3b	3 (16%)
- Fascia dehiscence	
- Paralytic ileus	
- Avital distal anastomosis of ureter-ileal conduit junction	
Score 4	1 (5%)
- Resuscitation during end of procedure	

Abbreviations: SD = standard deviation; ASA = American Society of Anaesthesiologists; PCa = prostate cancer; VUAS = Vesico-urethral anastomosis stenosis

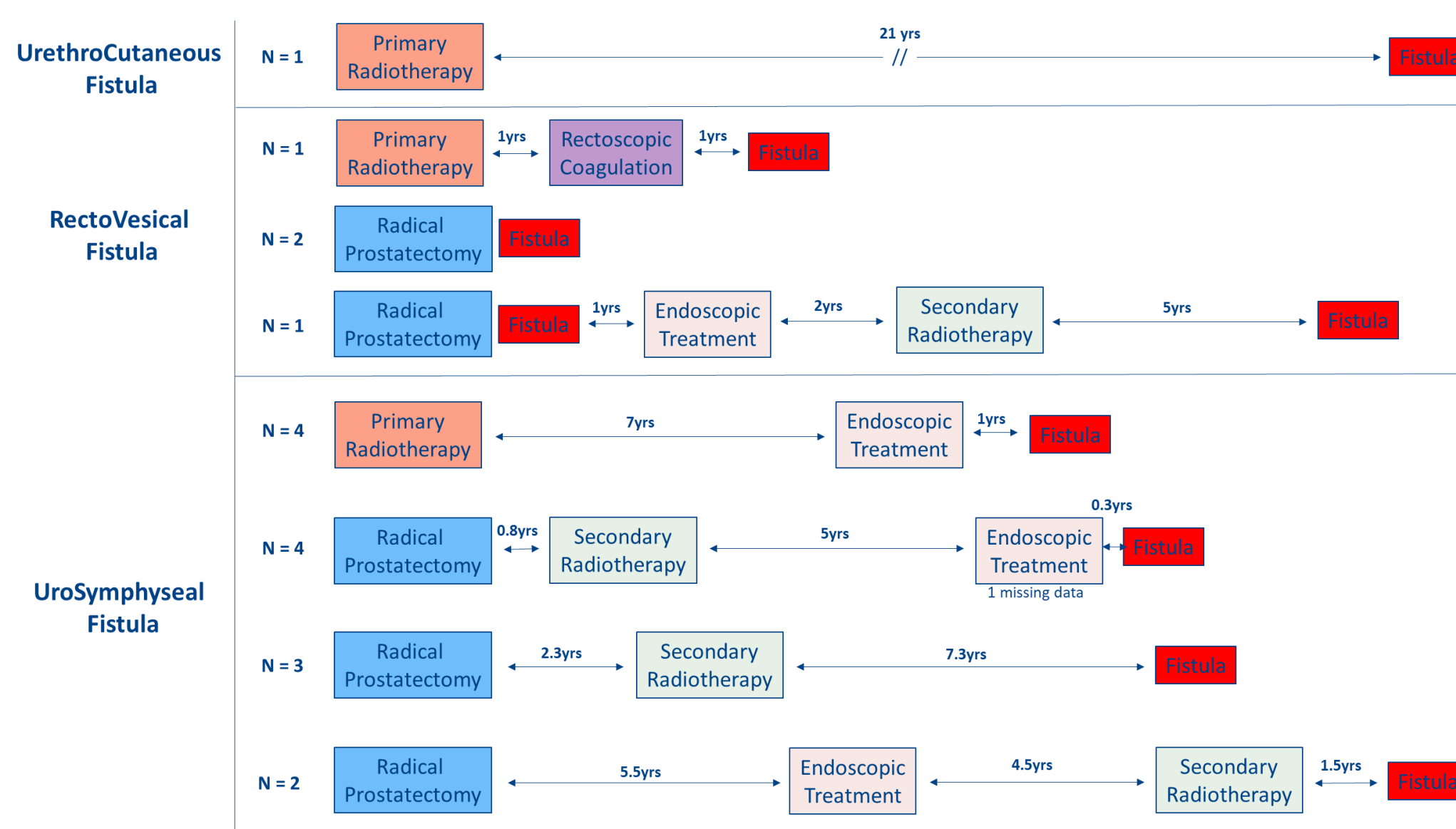


Figure 1. Disease course to fistula development after prostate cancer treatment. Years (yrs) are presented as average