



Comprehensive 3D Pelvic Floor Ultrasonography with emphasis on endovaginal (EVUS) and endoanal imaging (EAUS)

W19, 15 October 2012 14:00 - 18:00

| Start | End | Topic | Speakers |
|-------|-------|-------------------------------------------------------------------------------------------------------|-------------------------------------------------------------------------------------------------------------------------------------------|
| 14:00 | 14:10 | Introduction: Pre-test, Course objectives, clinical background and rationale for pelvic floor imaging | <ul style="list-style-type: none"> • S Abbas Shobeiri |
| 14:10 | 14:30 | Anatomical basis of pelvic floor ultrasonography | <ul style="list-style-type: none"> • S Abbas Shobeiri |
| 14:30 | 14:50 | 2D/3D, and functional US imaging of the lateral and anterior compartment; case studies | <ul style="list-style-type: none"> • S Abbas Shobeiri |
| 14:50 | 15:10 | 2D/3D, and functional US imaging of posterior compartment; case studies | <ul style="list-style-type: none"> • Giulio Aniello Santoro |
| 15:10 | 15:30 | Ultrasound instrumentation, techniques, and methodology and visualization of artefacts | <ul style="list-style-type: none"> • Andrzej Pawel Wieczorek |
| 15:30 | 16:00 | Break | None |
| 16:00 | 16:15 | Video | <ul style="list-style-type: none"> • S Abbas Shobeiri |
| 16:15 | 17:00 | Case studies | <ul style="list-style-type: none"> • Giulio Aniello Santoro • S Abbas Shobeiri • Andrzej Pawel Wieczorek |
| 17:00 | 17:50 | Hands-on ultrasound imaging | All |
| 17:50 | 18:00 | Post-test, Forum: Discussion, Questions and Answers | All |

Aims of course/workshop

Competence in performing comprehensive 3D ultrasound evaluation of the pelvic floor. After attending this Workshop, the participants should be able to perform a transperineal, endovaginal, and endoanal pelvic floor ultrasound and use the desktop 3D software to obtain basic measurements.

Educational Objectives

A manuscript pertaining to the educational value of this workshop received 2010 American Urogynecologic Society's best educational award. The workshops have consistently received high marks from the attendees. The workshop's unique structure and utilization of ultrasound phantoms gives the attendees an opportunity for hands-on operation of the ultrasound machine, transducers, and manipulation of 3D volumes.

Many new imaging techniques have been developed for the evaluation of pelvic floor disorders. Studies by various investigators have elucidated the anatomy and function of the pelvic floor. Imaging modalities require extensive comprehension of the pelvic floor anatomy. Damage to pelvic floor structures affects the structural integrity and function of the pelvic organs.

Ultrasonography has emerged as a relatively easy to perform, cost-effective, and widely available technique for specialized imaging of pelvic floor structures.

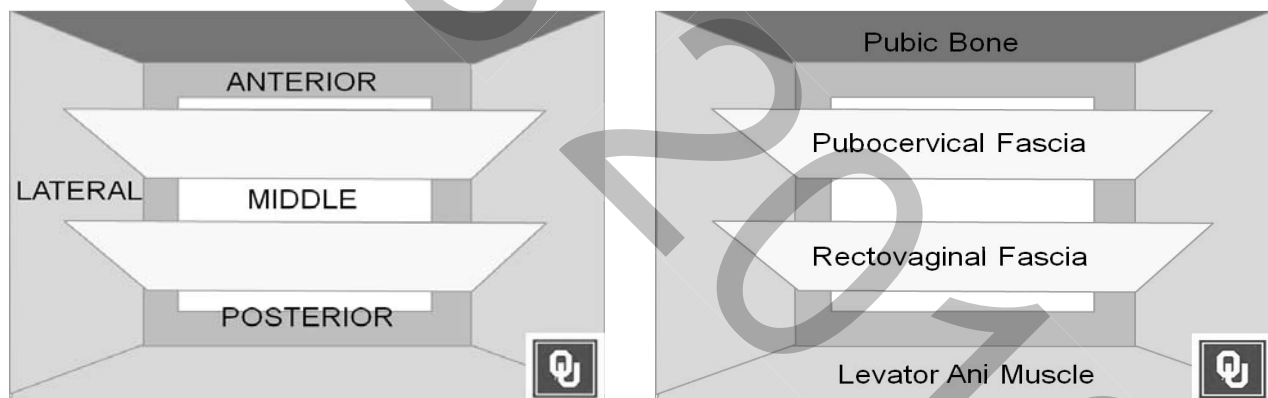ICS 2012 W19 Workshop Outline

Chairman: S. Abbas Shobeiri, MD (USA)

| | |
|--------------------------------------------------------------------------|---------------------------------------------------------------------------------------------------------------------------------------------------------------------------------------------------------------------------------------------------------------------------------------------------------------------------------------------------------------------------------------------------------------------------------------------------------------------------------------------------------------------------------------------------------------------------------------------------------------------------------------------------------------------------------------------------------------------------------------------------------------------------------------------------------------------------------------------------------------------------------------------------------------------------------------------------------------------------------------------------------------------------------------------------------------------------------------------------------------------------------------------------------------------------------------------------------------------------|
| <p>Title of workshop</p> | <p>Comprehensive 3D Pelvic Floor Ultrasonography with emphasis on endovaginal (EVUS) and endoanal imaging (EAUS)</p> |
| <p>Brief description/outline of workshop (Max 1000 words)</p> | <p>Outline of Workshop Program:</p> <p>1400-1410: Introduction: Pre-test, Course objectives, clinical background and rationale for pelvic floor imaging S. Abbas Shobeiri</p> <p>1410-1430 Anatomical basis of pelvic floor ultrasonography S. Abbas Shobeiri</p> <p>1430-1450 2D/3D, and functional US imaging of the lateral and anterior compartment; case studies S. Abbas Shobeiri</p> <p>1450-1510 2D/3D, and functional US imaging of posterior compartment; case studies Giulio Santoro</p> <p>1510-1530 Ultrasound instrumentation, techniques, and methodology and visualization of artifacts Pawel Wieczorek</p> <p>1530-1600 Break</p> <p>1600-1610 Video</p> <p>1610-1715 Live demonstration:</p> <ol style="list-style-type: none"> 1) Wieczorek: Use 8802 transducer for 2D transperineal imaging 2) Wieczorek: Use 2052 transducer Vaginal / 8848 anterior imaging 3) Santoro: Use 8848 Posterior Imaging / 2052 transducer Anal <p>1715-1750 Case studies</p> <p>1750 Post-test Forum: Discussion, Questions and Answers</p> <p>1800 Adjourn</p> |

Anatomical basis of pelvic floor ultrasonography

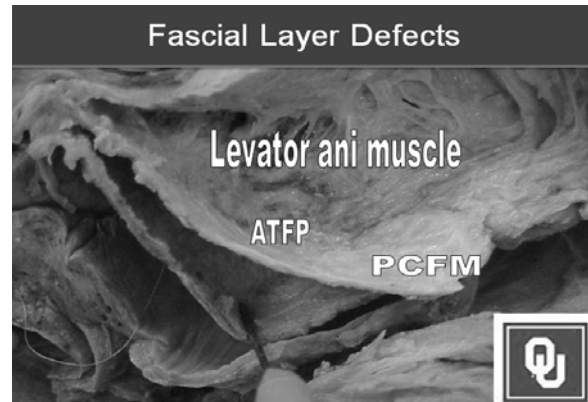
The pelvic organs rely on their connective tissue attachments to the pelvic walls and support from the levator ani muscles that are under neuronal control from the peripheral and central nervous systems. In our presentations, the term “pelvic floor” is used broadly to include all the structures supporting the pelvic cavity rather than the restricted use of this term to refer to the levator ani group of muscles.



The female pelvis can naturally be divided into anterior and posterior and lateral compartments. The genital tract (vagina and uterus) divides the anterior and posterior compartments through lateral connections to the pelvic sidewall and suspension at its apex. The levator ani muscles form the bottom of the pelvis. The organs are attached to the levator ani muscles when they pass through the urogenital hiatus and are supported by these connections.

Anterior Compartment


Anterior compartment support depends on the connections of the vagina and periurethral tissues to the muscles and fascia of the pelvic wall via the arcus tendineus fascia pelvis. Anatomically, the endopelvic fascia refers to the areolar connective tissue surrounding the vagina. It continues down the length of the vagina as loose areolar tissue surrounding the pelvic viscera.



The vagina is made up of three layers- epithelium, muscularis, and adventitia. The term “perineal membrane” consists of a single connective tissue membrane, with muscle lying immediately above. The perineal membrane lies at the level of the hymen and attaches the urethra, vagina, and perineal body to the ischiopubic rami. The compressor urethrae and urethrovaginal sphincter muscles are associated with the cranial surface of the perineal membrane.

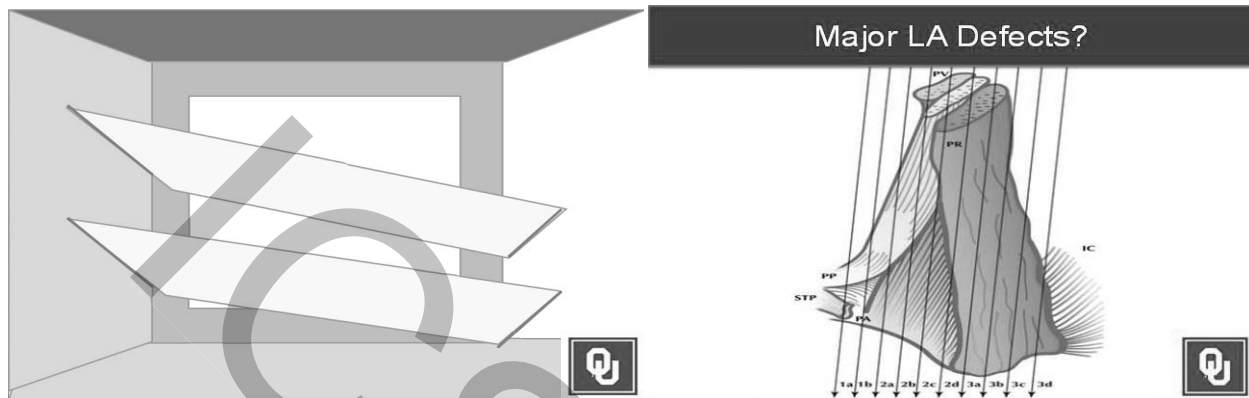
Posterior Compartment

The posterior vagina is supported by connections between the vagina, the bony pelvis, and the levator ani muscles. The lower one-third of the vagina is fused with the perineal body.



Lateral Compartment and the Levator Ani Muscles

Below and surrounding the pelvic organs are the levator ani muscles. When these muscles and their covering fascia are considered together, the combined structures are referred to as the pelvic diaphragm. There are three major components of the levator ani muscle.

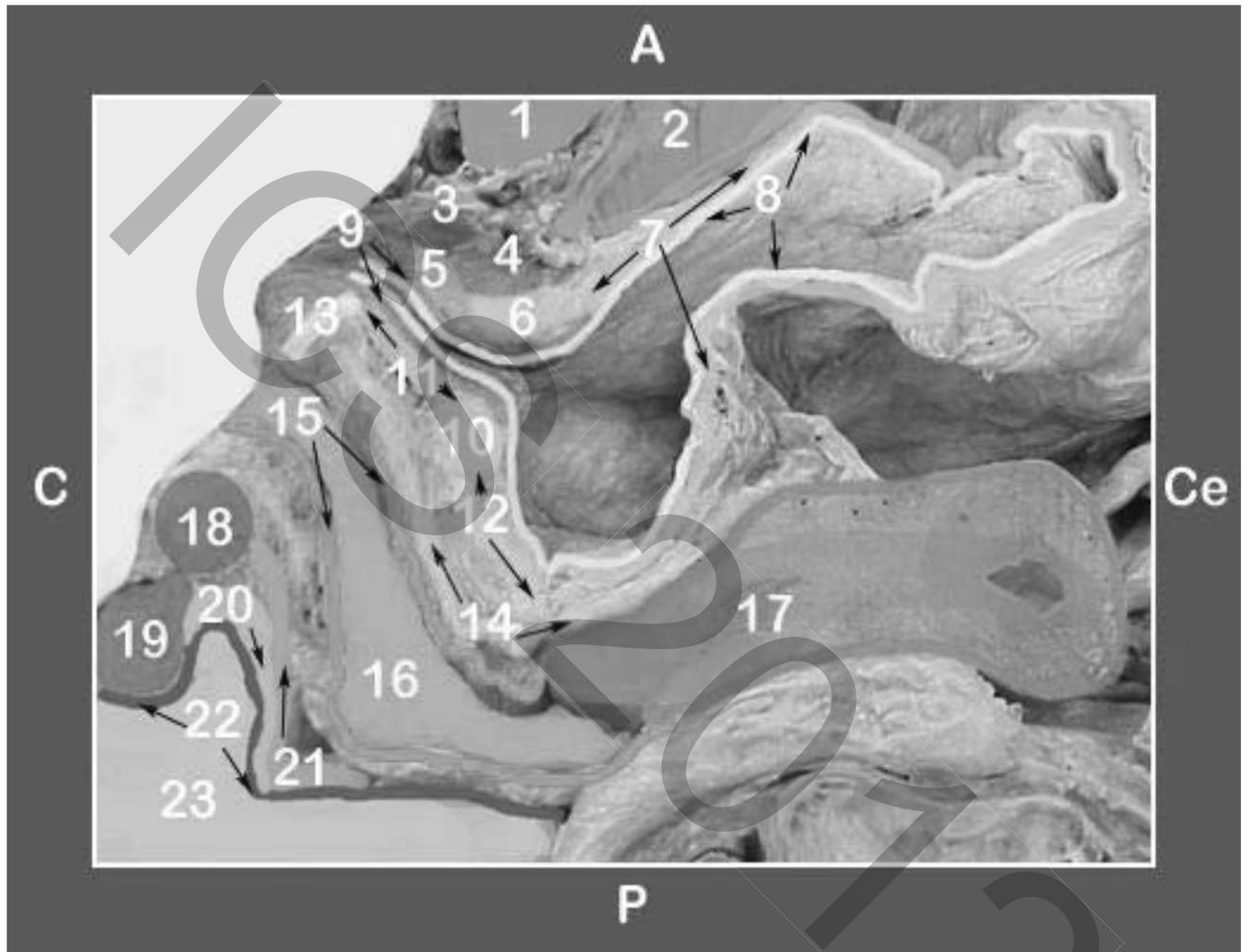


The iliococcygeal portion forms a thin, relatively flat, horizontal shelf that spans the potential gap from one pelvic sidewall to the other. The pubovisceral (also known as the pubococcygeus) muscle attaches the pelvic organs to the pubic bone while the puborectal muscle forms a sling behind the rectum. The lesser known subdivisions of the levator are pubovaginal, puboanal and the puboperineal muscles. Once the pelvic musculature becomes damaged and no longer holds the organs in place, the ligaments are subjected to excessive forces.

Nerves

There are two main nerves that supply the pelvic floor relative to pelvic organ prolapse. One is the pudendal nerve that supplies the urethral and anal sphincters and perineal muscles and the other is the nerve to the levator ani that innervates the major musculature that supports the pelvic floor. These are distinct nerves with differing origins, courses and insertions. The nerve to the levator originates from S3 to S5 foramina, runs inside of the pelvis on the cranial surface of the levator ani muscle and provides the innervation to all the subdivisions of the muscle. The pudendal nerve originates from S2 to S4 foramina runs through Alcock's canal which is caudal

to the levator ani muscles. The pudendal nerve has three branches: the clitoral, perineal and inferior hemorrhoidal which innervate the clitoris, the perineal musculature, and inner perineal skin, and the external anal sphincter respectively. The levator ani muscle often has a dual somatic innervation with the levator ani nerve as its constant and main neuronal supply.



Sagittal view of a right hemipelvis

Structures are identified in lateral view with color coding.

A) Anterior, C) Caudad, P) Posterior, Ce) Cephalad, 1) Pubic bone, 2) Space of Retzius, 3) Urethrovaginal sphincter, 4) Compressor urethrae, 5) Smooth muscle layer, 6) Anterior aspect of trigonal ring, 7) Detrusor muscle, 8) Uroepithelium, 9) Urethral venus plexus, 10) Posterior trigonal ring, 11) Trigonal plate, 12) Vesical trigone, 13) Perineal membrane, 14) Pubocervical fibromuscularis, 15) Vaginal mucosa, 16) Vagina, 17) Uterus, 18) Perineal body, 19) External anal sphincter, 20) Internal anal sphincter, 21) Rectovaginal septum, 22) Anal mucosa, 23) Anal canal

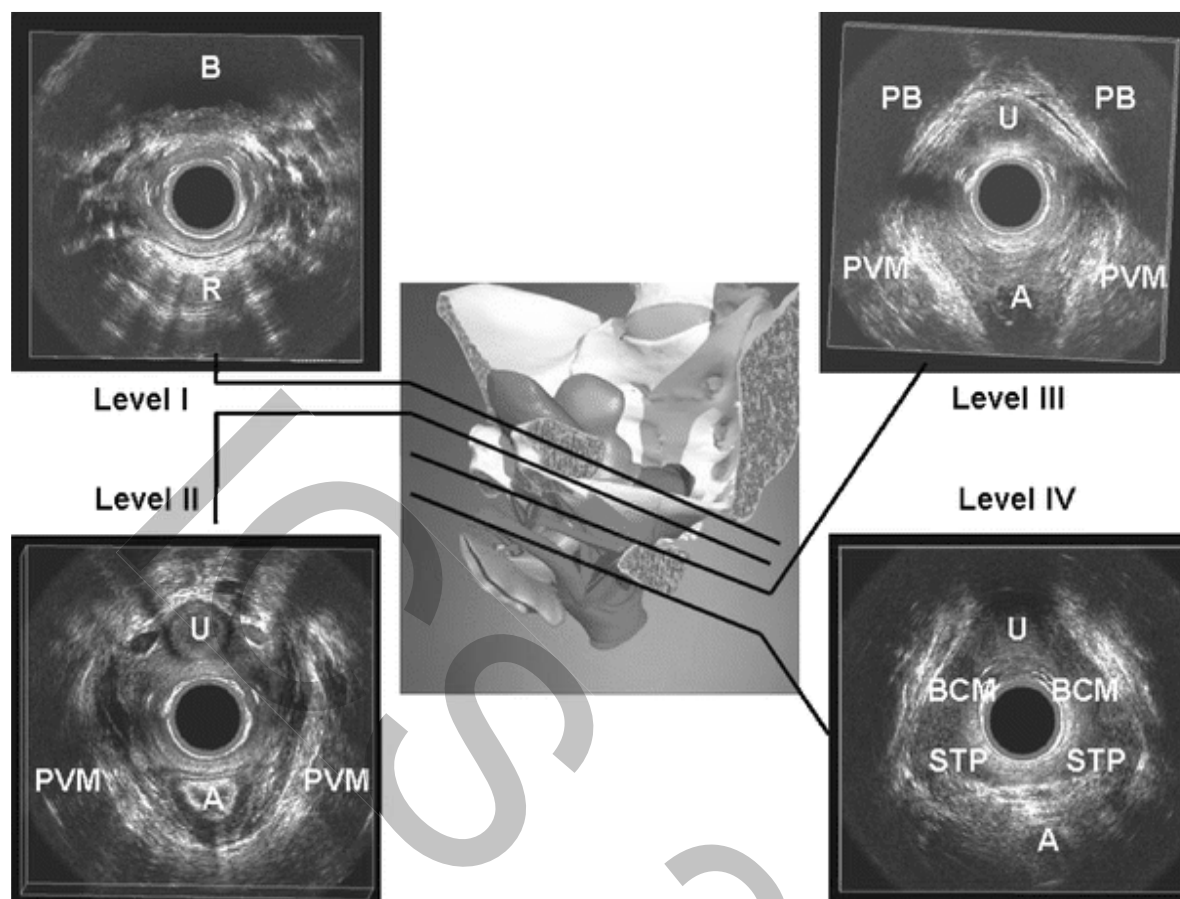
Introduction to ultrasound: Instrumentation, techniques, and methodology for pelvic floor imaging

3D-US is a modality that involves acquisition of sonographic volumes as opposed to the single tomographic slices traditionally viewed on 2D sonography. Adding the third dimension means that a pixel is transformed into a small 3D picture element called a voxel. Ideally, a voxel should be a cubic structure; however, with the current technology, the dimension in the Z-plane is larger than that in the X- and Y-planes (low-resolution 3D-US). Latest technical developments have improved the resolution between two transaxial images to 0.2 mm with data volumes consisting of voxel sizes of $0.15 \times 0.15 \times 0.2$ mm (high-resolution 3D-US). Because of this resolution in the longitudinal plane, which is close to the axial and transverse resolution of the 2D image, this technique ensures true dimensions of the 3D data cube also in the reconstructed Z-plane and provides accurate distance, area, angle, and volume measurements.

Technical aspects of 3D endovaginal ultrasound

No patient preparation is required. We recommend the patient to have a comfortable volume of urine in the bladder. No rectal or vaginal contrast is used. The patient is placed in dorsal lithotomy and the probe is inserted into the vagina in a neutral position to avoid excessive pressure on surrounding structures that might distort the anatomy.

Two different ultrasonographic techniques can be used to develop the 3D images. Assessment was initially performed with a 9- to 16-MHz rotational 360° transducer (type 2050; B-K Medical, Herlev, Denmark) to provide a topographical overview of the pelvic floor anatomy. The 2050 transducer has a built-in 3D automatic motorized system that allows an acquisition of 300 transaxial images over a distance of 60 mm in 60 s without requiring any movement relative to the investigated tissue. The 3D data automatic acquisition started slightly above the bladder neck to end below the external meatus of the urethra. We defined four standard levels of assessment in the axial plane :



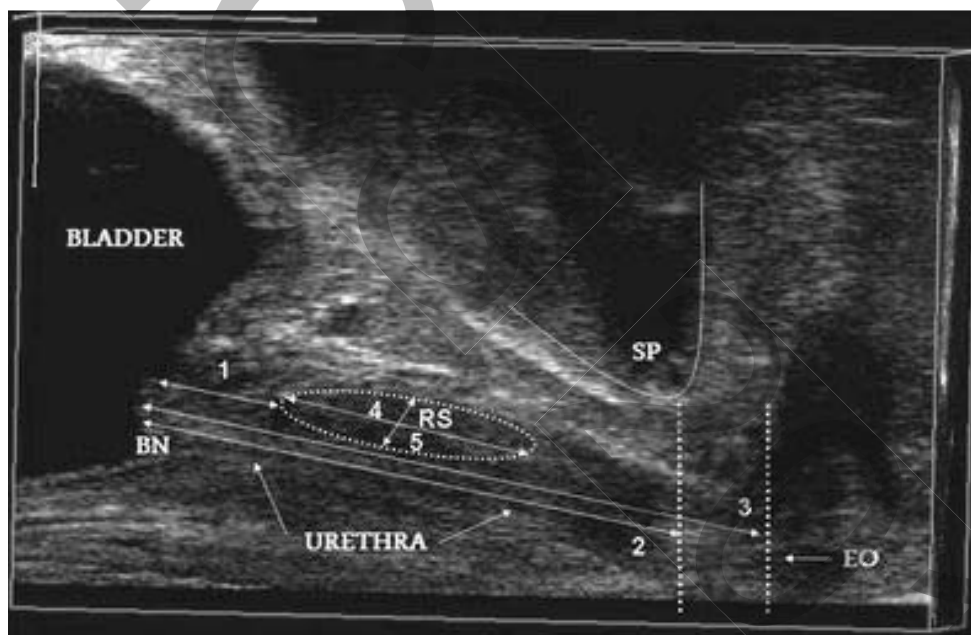
Four standard levels of assessment of the female pelvic floor with endovaginal ultrasound (2050 transducer). The *right side of the image* is left side of the patient. *B* bladder, *R* rectum, *U* urethra, *A* anal canal, *PVM* pubovisceral muscle, *PB* pubic bone, *BCM* bulbocavernosus muscle, *STP* superficial transverse perineal muscle

Endovaginal ultrasound can be with a linear transducer 21 mm in diameter (type 8848; B-K Medical), frequency range 5–12 MHz, focal range 3–60 mm, to assess anatomy of the anterior and posterior compartments. The linear array of this transducer has a long contact surface (65 × 5.5 mm) and a 90° imaging orientation to the longitudinal axis. A computer-controlled acquisition of 350 parallel longitudinal 2D images in 25 s was obtained by connecting the probe to a 180° rotation mover (UAO513 B-K Medical). For the assessment of the anterior compartment, rotation is performed from the right side (9 o'clock position) to the left side (3 o'clock position) of the patient, and for the assessment of the posterior compartment, from 3 to 9

o'clock position. To evaluate the vascular pattern of the urethra, three-dimensional acquisition is repeated using color doppler.

2D/3D, and functional US imaging of anterior and the lateral compartments

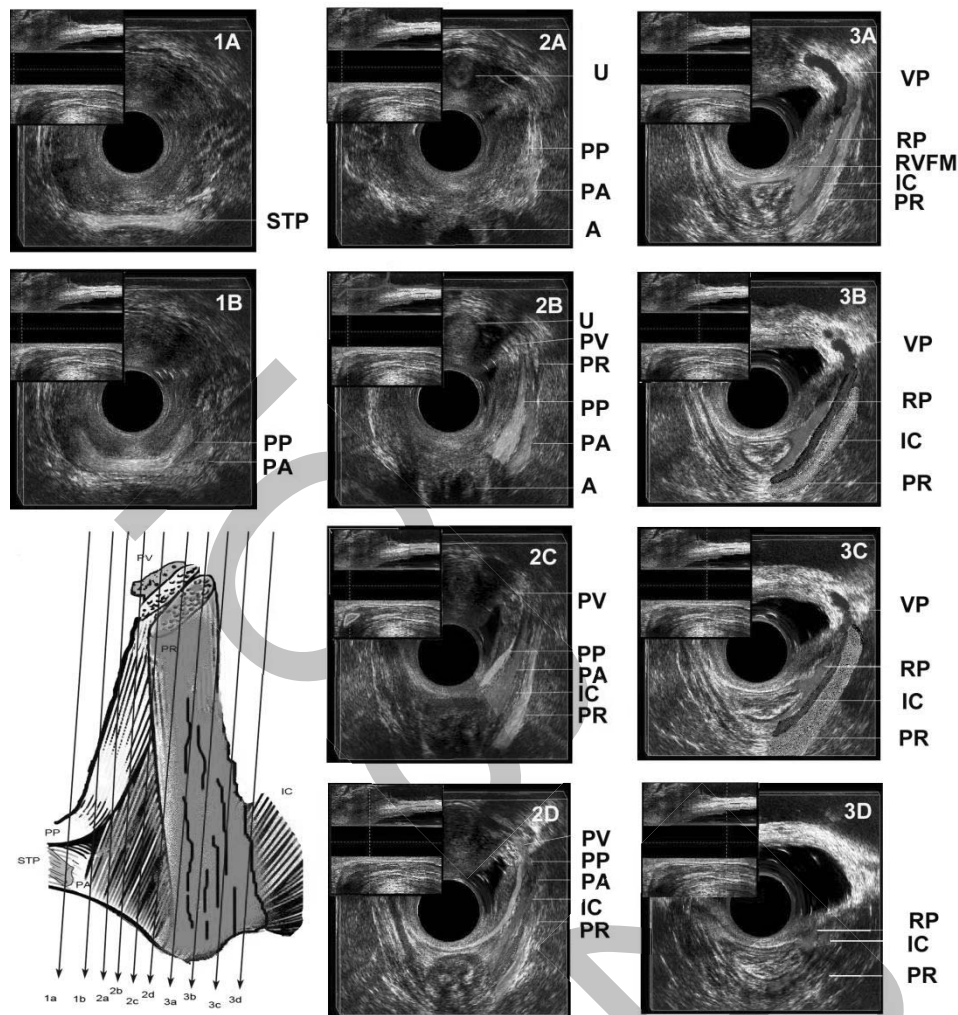
Assessment of the anterior compartment in the midsagittal section includes measurements of the length (from bladder neck to the external urethral orifice) and thickness of the urethra, bladder–symphysis distance (from the bladder neck to the lowest margin of the SP), rhabdosphincter (RS) length and thickness, and the distance between bladder neck and RS.



Anterior compartment is assessed in the midsagittal plane. Measurements include: bladder neck–RS distance (1), bladder–symphysis distance (2), urethral length (3), RS length (4), and thickness (5). Image was obtained by the 8848 transducer. *BN* bladder neck, *RS* rhabdosphincter, *SP* symphysis pubis, *EO* external urethral orifice

Given that we employ concepts such as pelvic floor spasm, levator spasm, and pelvic floor weakness, understanding the basic concepts of pelvic floor musculature is essential to formulating a clinical opinion. The area posterior to the pubic bone is dense with bands of intertwined levator ani muscles which defy conventional description of the levator ani being consisted of puborectalis, pubococcygeous and the iliococcygeous. The anatomy of distal

subdivisions of the levator ani muscle was further described in a recent study. Using a nomenclature based on the attachment points of different subdivisions of the levator ani muscles, the muscles posterior to the pubic bone are identified as pubovaginalis, puboanalis, and the puboperinealis as the subdivisions of the pubovisceralis. Because puboanalis, pubovaginalis, and the puboperinealis are small, they are proven hard to visualize in rigid axial, coronal, and sagittal views of the magnetic resonance imaging. The levator ani muscle is arranged as a unique 3-dimensional structure which lends itself to dynamic imaging by ultrasonography. Endovaginal 3D ultrasound technique allows us to document the complex anatomy of the levator ani muscle in graphic detail and in a permanent, objective way.



Levator ani subdivisions seen at different levels.

Midline structures are identified in lateral views with corresponding colors in the picture inserts at the upper left corner of the ultrasound images at each level. The green vertical line in the insert corresponds to the relative position in the vagina where the image is obtained.

A) Level 1A: At 0 cm, the first muscle seen is superficial transverse perinei (Green) with mixed echogenicity.

B) Level 1B: Immediately cephalad to superficial transverse perinei is puboperinealis (Yellow) that can be traced to PB with manipulation of 3D cube. It comes in at a 45 degree angle as a mixed echoic band to join the perineal body. Lateral to it, the puboanalis is seen as a hypoechoic triangle (Pink).

C) Level 2A: This level marks the attachment of the muscles to the pubic arch. The external urethral meatus is visible (Dark red). Puboperinealis and puboanalis insertions are highlighted.

D) Level 2B: Pubovaginalis (Blue) and puborectalis (Mustard) insertion come to view. The urethra and the bladder are outlined (Red) in the lateral view.

E) Level 2C: The heart shape vaginal sulcus (outlined in Red) marks the pubovaginalis insertion. Iliococcygeous fibers (Red) come into view. Perineal body is outlined in the lateral view.

F) Level 2D: Puboanalis is starting to thin out. Puborectalis is seen in the lateral view.

G) Level 3A: Puboperinealis and puboanalis become obscure. Anatomically, puboanalis becomes a thick fibromuscular layer forming a tendinous sheet, rectal pillar (RP). Perivesical venous plexus are prominent (Purple). Rectovaginal fibromuscularis (RVFM) is shown (Green) in sagittal view as a continuous mixed echogenic structure approaching the perineal body and laterally attaching to RP.

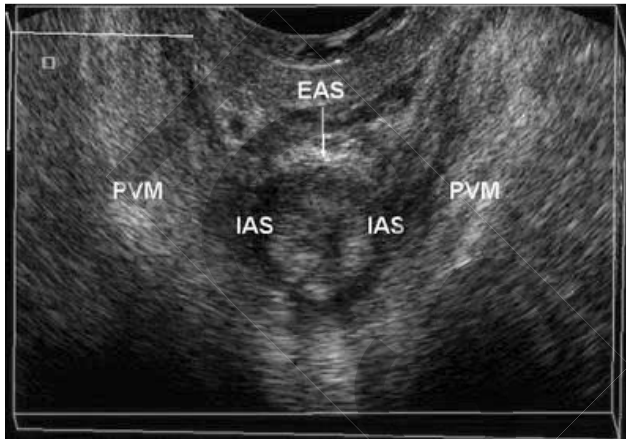H) Level 3B: Rectal pillar (Orange) is easily seen. The iliococcygeous becomes prominent and widens.

I) Level 3C: The iliococcygeous becomes widens further and inserts into ATFP.

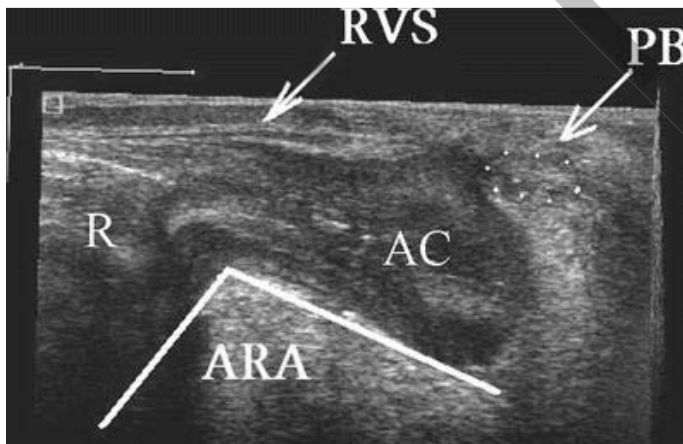
J) Level 3D: Puborectalis and fade out of view. Puborectalis (Mustard) and Iliococcygeous (Red) are outlined in the lateral view showing their entire course.

2D/3D, and functional US imaging of posterior compartment

Assessment of the posterior compartment included the measurements of the internal anal sphincter (IAS) and external anal sphincter (EAS). In the axial plane, the IAS appears as a concentric hypoechoic ring surrounding a more echogenic central mucosa and the EAS appeared as a concentric band of mixed echogenicity surrounding the IAS.



Axial view of the anal complex (8848 transducer). The external anal sphincter (*EAS*) appears as a hyperechoic ring surrounding the hypoechoic ring of the internal anal sphincter (*IAS*). *PVM* pubovisceral muscle



Longitudinal view of the posterior compartment. Image was obtained by 8848 transducer. *R* rectum, *AC* anal canal, *RVS* rectovaginal space, *PB* perineal body, *ARA* anorectal angle

The current gold standard for the assessment of the posterior compartment is considered to be endoanal US (EAUS). Endovaginal US offers an alternative imaging modality of the anal

sphincter complex and has proven to be as accurate as EAUS. Anal sphincters thickness is comparable to the measurements reported in the literature by using EAUS, TLUS, or MRI. However, regardless of the absolute values of the anal sphincters, the most relevant utility of EVUS applies in the detection of localized EAS defects when EAUS cannot depict any sphincter damage in order to confirm or exclude EAUS findings in patients with idiopathic fecal incontinence, passive fecal incontinence, or obstructive defecation disorders. The most important advantage of EVUS compared to EAUS is the access to the longitudinal plane that allows the assessment of the ARA, the RVS, and the perineal body.

Ultrasound scanning: Artifacts, tips, and imaging of tapes and meshes

High-resolution 3D-EVUS provides a detailed assessment of the pelvic floor both for identifying and measuring specific anatomic structures and for understanding their complex spatial arrangements. It is relatively easy to perform, time efficient, correlates well with other imaging modalities, and delivers additional information on urethral complex and superficial perineal structures at the same time. It is quite likely that this procedure will become helpful in the assessment of SUI, voiding dysfunction, pelvic pain, and dyspareunia, FI, obstructed defecation, and POP. Moreover, the possibility of the storage of information might be useful for PFD data registry.

References:

Santoro GA, Wieczorek AP, Stankiewicz A, et al. High-resolution three-dimensional endovaginal ultrasonography in the assessment of pelvic floor anatomy: a preliminary study. *Int urogynecology J.* 2009;20:1213-22.

Shobeiri SA, LeClaire E, Nihira MA, Quiroz LH, O'Donoghue D. Appearance of the Levator Ani Muscle Subdivisions in endovaginal 3-Dimensional Ultrasonography. *Obstet & Gynecol* 2009;114:66-72.

Wieczorek AP, Magdalena MW, Stankiewicz A, et al. The assessment of normal female urethral vascularity with Color Doppler endovaginal ultrasonography: preliminary report. *Pelviperrineology* 2009;28:59-61.



Notes

Record your notes from the workshop here