

## W28: ICS Core Curriculum (Free): The Ethics of Female Genital Mutilation (FGM) and Other Urogenital Interventions: An Interactive Workshop

Workshop Chair: Nina Davis, United States

13 September 2017 16:30 - 18:00

Start	End	Topic	Speakers
16:30	16:35	Welcome and introduction	Nina S. Davis
16:35	16:50	Sociocultural Basis of FGM	Cristina Naranjo Ortiz
16:50	17:30	Case study: FGM 1) issue of consent 2) medical implications 3) legality of reinfibulation	Ruwan Fernando
17:30	17:55	Genital Surgery in the New World 1) male circumcision 2) intersex 3) cosmetic surgery	Tamara Dickinson
17:55	18:00	Summary/Take-home messages	Cristina Naranjo Ortiz

### Speaker PowerPoint Slides

Please note that where authorised by the speaker all PowerPoint slides presented at the workshop will be made available after the meeting via the ICS website [www.ics.org/2017/programme](http://www.ics.org/2017/programme). Please do not film or photograph the slides during the workshop as this is distracting for the speakers.

### Aims of Workshop

Discussion in this advanced, interactive seminar will be organized around case studies and up-to-the-minute sociopolitical, medicolegal and ethical policies, guidelines and practices surrounding FGM and its consequences as well as parallel consideration of other genital altering procedures such as cosmetic surgery, male circumcision or those performed on intersex children.

### Learning Objectives

1. Identify the different types of FGM
2. Understand the ethical basis for opposition to FGM
3. Compare the ethical justification for performing surgeries such as male circumcision or cosmetic genital procedures
4. Delineate the evolution and ethical basis for the new WHO guidelines for the management of intersex disorders

### Learning Outcomes

By the end of the course, the participant will be able to

- Describe the types of FGM
- Outline the ethical considerations in FGM and other procedures affecting the genitalia
- Discuss the legal considerations in performing reinfibulation
- Summarise governmental and institutional policies relating to FGM and genital procedures
- Compare the ethical considerations raised by various types of genital surgery

### Target Audience

All delegates interested in global health and, in particular, the ethical aspects of female genital mutilation (FGM) and other surgical procedures that affect the urogenital tract.

### Advanced/Basic

Advanced.

### Suggested Reading

1. Obermeyer CM. The consequences of female circumcision for health and sexuality: an update on the evidence. *Culture, Health & Sexuality*, September–October 2005; 7(5): 443–461.
2. Morison, L., Scherf, C., Ekpo, G., Paine, K., West, B., Coleman, R. and Walraven, G. The long-term reproductive health consequences of female genital cutting in rural Gambia: a community-based survey. *Tropical Medicine and International Health*. 2001; 6: 643–653.
3. Okonofua, F., Larsen, U., Oronsaye, F., Snow, R. and Slinger, T. The association between female genital cutting and correlates of sexual and gynaecological morbidity in Edo State, Nigeria. *British Journal of Obstetrics & Gynaecology*. 2001; 109, 1089–96.
4. *Realizing sexual and reproductive rights: a human rights framework*. London: Amnesty International; 2012. ([http://www.amnesty.ca/sites/amnesty/files/act\\_350062012\\_english.pdf](http://www.amnesty.ca/sites/amnesty/files/act_350062012_english.pdf), accessed 27 April 2016).
5. UN Fact Sheet: Intersex – Free and Equal. ([https://www.unfe.org/system/unfe-65-Intersex\\_Factsheet\\_ENGLISH.pdf](https://www.unfe.org/system/unfe-65-Intersex_Factsheet_ENGLISH.pdf), accessed 2 February 2017).

6. BMJ Symposium on circumcision: The law and ethics of male circumcision: guidance for doctors. J Med Ethics. 2004; 30: 259-263.
7. Goodman MP, Goldstein AT, Jutrzonka SL. Chapter 6. Ethical considerations of female plastic/cosmetic surgery in Female Genital Plastic and Cosmetic Surgery, New York: Wiley, 2016.
8. Hughes IA, Houk C, Ahmed SF et al. Consensus statement on management of intersex disorders. Arch Dis Child. 2006; 91(7): 554-563.

### **Participant Summaries:**

**Cristina Naranjo Ortiz, PT, PhD, Physiotherapist, Spain, [c\\_naranjoortiz@outlook.com](mailto:c_naranjoortiz@outlook.com)**

Female Genital Mutilation (FGM), female genital cutting, infibulation or female circumcision are all terms that refer to the ancient practise of removing all or part of the female external genitalia. It is practised in many African countries, the Middle East and Asia as well as in immigrant communities where members of participating sects reside. Genital cutting commonly is carried out between birth and age 15. Four types of FGM are described. FGM is carried out in a ritualistic fashion and is promoted as a means of promoting a woman's purity, modesty and beauty. There are no known medical benefits. Short- and long-term complications of the procedure can be quite severe including infections, difficulty urination or menstruating, chronic pain, difficulty conceiving, psychological distress, complicated deliveries and even death. Although numerous governments have passed laws against the practise and numerous NGOs have published statements decrying the procedures, they continue to be performed.

**Ruwan Fernando, MBBS, MS (O&G), FRCOG, MD  
Consultant Obstetrician and Gynecologist, UK, [Ruwan.Fernando@imperial.nhs.uk](mailto:Ruwan.Fernando@imperial.nhs.uk)**

FGM, being an ancient practice, is often described as a barbaric and anachronistic ritual. It has also been characterised as torture and a means of victimization of women. Some sociologists and anthropologists argue, however, that the use of such inflammatory language represents a lack of respect for the cultural context of FGM.- placing a moral judgment on a procedure that is an established ritual in many ancient cultures.

The ethical principles that underlie the objections to FGM are autonomy, beneficence and non-maleficence. Since medical practitioners are rarely involved in the procedures, one might argue that cultural considerations override these precepts of modern medical bioethics. More relevant, perhaps, is the larger question of human rights, specifically, a woman's right to consent and self-determination. These are the cornerstones of anti-FGM activism. Ultimately, it must come down to a question of the promotion of women's health. The legal restrictions on FGM stem from concerns for the long-term effects of FGM on a woman's overall health and quality of life.

**Tamara Dickinson MSN, APRN, AGPCNP-BC, CURN, CCCN  
Nurse Practitioner, United States, [Tamara.Dickinson@UTSouthwestern.edu](mailto:Tamara.Dickinson@UTSouthwestern.edu)**

Circumcision of a male infant parallels, in some respects, the performance of FGM in that a decision is being made for the child by a surrogate. An argument can be made that circumcision should be withheld until the child is capable of making a decision for himself with the exception of ritual circumcision which must occur at a specific point in time. Whereas FGM has no medical justification, male circumcision has well-established health benefits, among them the prevention of penile cancer and of transmission of sexually transmitted infections such as Human Papilloma Virus (HPV) and Human Immunodeficiency Virus (HIV). Since these benefits still accrue when circumcision is performed well into adolescence, the argument for early circumcision largely rests on the ease and relative reduction in pain when circumcision is performed on a newborn's phallus.

In the past, well-meaning paediatric surgeons performed major reconstructive procedures on intersex children to allow their genitalia to approximate social and cultural norms with far-reaching consequences, as affected children were often raised in the gender that corresponded to their genital configuration instead of their genotypic sex. This paternalistic lack of regard by the medical establishment for the children's autonomy led to gender dysphoria and other profound psychological consequences. In parallel with progress in the understanding and tolerance of gender and sexual fluidity in western culture, terminology has been adjusted and guidelines for the management of intersex disorders have been revised to provide a more ethical framework for the treatment of affected individuals.

In the case of people with intersex disorders, their sense of self confidence and self-worth is linked to their physical make-up. Similarly, the argument is made that cosmetic genital surgery is justified by its ability to improve the feelings people have about their genitalia and, hence, their sexuality. The question then arises as to when plastic surgeons or other surgeons who perform such procedures are preying on individuals' sense of inadequacy. In the case of cosmetic genital surgery, then, what is the ethical basis for providing such services?



## The Ethics of Female Genital Mutilation (FGM) and Other Urogenital Interventions: An Interactive Workshop

MODERATORS  
Cristina Naranjo-Ortiz  
Ruwan J. Fernando  
Tamara Dickinson



Nina S. Davis

Affiliations to disclose<sup>†</sup>:

Medical Education Speakers Network

\* All financial ties (over the last year) that you may have with any business organisation with respect to the subjects mentioned during your presentation

Funding for speaker to attend:

Self-funded

Institution (non-industry) funded

Sponsored by:



Cristina Naranjo-Ortiz

Affiliations to disclose<sup>†</sup>:

ICS TRUSTEE

\* All financial ties (over the last year) that you may have with any business organisation with respect to the subjects mentioned during your presentation

Funding for speaker to attend:

Self-funded

Institution (non-industry) funded

Sponsored by:



Ruwan J. Fernando

Affiliations to disclose<sup>†</sup>:

**Laborie** - Speaker Honorarium , Fellowship, Travel grants  
**AMS** - Speaker Honorarium  
**Astellas** - Speaker Honorarium, Trial participation, Fellowship, Travel grants  
**Pfizer** - Speaker Honorarium, Trial participation, Fellowship, Travel grants

\* All financial ties (over the last year) that you may have with any business organisation with respect to the subjects mentioned during your presentation

Funding for speaker to attend:

Self-funded

Institution (non-industry) funded

Sponsored by:



Tamara Dickinson

Affiliations to disclose<sup>†</sup>:

None

\* All financial ties (over the last year) that you may have with any business organisation with respect to the subjects mentioned during your presentation

Funding for speaker to attend:

Self-funded

Institution (non-industry) funded

Sponsored by:



## Sociocultural Basis of FGM

**Cristina Naranjo Ortiz, Ph.D**  
Anthropologist/Physiotherapist  
Faculty of Medicine – Complutense University  
Madrid, Spain

## WHAT IS FGM?



- Female genital mutilation, also known as female circumcision, excision or genital cutting, comprises all procedures that involve partial or total removal of the external female genitalia, or other injury to the genital organs for non-medical reasons, mostly carried out between infancy and age 15.
- The procedure has no health benefits for girls and women.
- Usually performed without permission and often against their will, it violates girls' right to make important decisions about their sexual health.

## FEMALE GENITAL MUTILATION



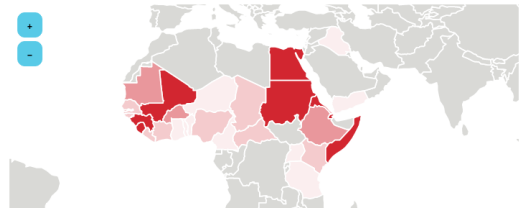
- At least 200 million girls and women alive today have undergone a form of female genital mutilation (FGM).
- If current trends continue, 15 million additional girls between ages 15 and 19 will be subjected to FGM by 2030.

## WHY DOES FEMALE GENITAL MUTILATION HAPPEN?



- Cultural beliefs are a strong factor in why this harmful practice takes place.
  - It is claimed to preserve chastity, cleanliness, family honour and preserves a girl for marriage.
  - It requires sensitive handling if we are to persuade communities that it is not a necessary part of a girl's education and coming of age ritual.

## WHERE DOES IT HAPPEN?



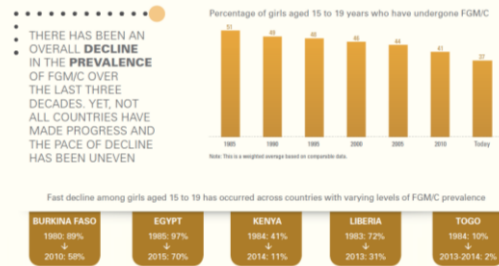
Although primarily concentrated in 30 countries in Africa and the Middle East, female genital cutting is a universal problem and is also practised in some countries in Asia and Latin America. The practice continues to persist amongst immigrant populations living in Western Europe, North America, Australia and New Zealand.

## WHAT ARE THE CONSEQUENCES?



- Procedures can cause severe bleeding and problems urinating immediately afterward
- Later, there can be cyst formation, infections, infertility, as well as complications of childbirth and increased risk of new-born deaths.
- Deaths from excision do happen as a result of haemorrhaging during or immediately after the procedure or infections in the following weeks.
- The lasting psychological effects on victims can be traumatic, often leading to long-term mental health issues and sexual dysfunction.

## DECLINE IN THE PREVALENCE



## ANTHROPOLOGY AND CULTURAL RELATIVISM



- One of the core tenets of anthropology is the idea of "cultural relativism".
- It is argued that all cultures should be considered equal, and that no one culture is superior to any other.
- For anthropologists, the study of other cultures should be free of bias and judgment in order to allow objective observations and recording.

## ANTHROPOLOGY AND CULTURAL RELATIVISM



- Anthropological and ethnographic inquiries of FGM/C have noted the same societal pressure.
- Even though some wish the practice to be stopped and do not wish their daughters to be circumcised, they are unable to change the societal norm. One anthropologist, interviewing a Muslim leader who opposed the extreme pharaonic procedure as "barbaric", said that his own daughters were, in the end, "pharaonized".
- "One could not go against custom, he said. Custom was too strong in the people. *No one could defy custom.*" (Lightfoot-Klein, 1989).

## *The Female Circumcision Controversy: An Anthropological Perspective*



- Ellen Gruenbaum has conducted research in Sudan and Sierra Leone on the practice of female genital cutting and the social movements against such "harmful traditional practices".
- In her book, *The Female Circumcision Controversy: An Anthropological Perspective*, she points out that Western outrage and Western efforts to stop genital mutilation often provoke a strong backlash from people in the countries where the practice is common: "The criticisms of outsiders are frequently simplistic and fail to appreciate the diversity of cultural contexts, the complex meanings and the conflicting responses to change."

## ANOTHER ANTHROPOLOGIC VIEW



- The concept of "choice" in a community that has long traditions about the subject of that choice, particularly ones connected with religion, is problematic
- How do we know that without religious and social pressure, female genital mutilation/cutting (FGM/C) is a "choice" in the sense of something that would be elected without that pressure?
- While FGM/C has been around for a long time, and is practiced by non-Muslims, it's been institutionalized (as has veiling) by many branches of Islam.
- Bettina Shell-Duncan, an anthropology professor at the University of Washington who has been studying the practice in many countries for years, suggests using the term "cutting" rather than "mutilation", which sounds derogatory and can complicate conversations with those who practice FGM/C.

## CULTURAL CONSIDERATIONS



- Shell-Duncan also challenges some common misconceptions around FGM/C, like the belief that it is forced on women by men.
- In fact, elderly women often do the most to perpetuate the custom.
- African girls are held down and "circumcised" against their will, but some of them voluntarily and joyfully partake in the ritual.
- Communities would surely abandon the practice once they learned of its negative health consequences.
- And yet, in Shell-Duncan's experience, most people who practice FGC recognize its costs—they just think the benefits outweigh them.

## AGAINST CULTURAL RELATIVISM



- It doesn't matter who perpetuates the custom, whether it be women or men. Society forces the practice on young girls, and religion not only allows it but in some cases urges it.
- Changing the word to "cutting" rather than "mutilation" is just semantics.
- Those trying to eliminate it should just call it "cutting the genitals" to those they're trying to persuade, but their motivation stems from believing it is, indeed, mutilation.
- And of course if doing something integrates a woman into her culture, she may do it "joyfully"—after all, she is joining the pack—but does she do it "voluntarily"? In a culture where it's the norm, and rejecting it leads to ostracism, what does "voluntarily" even mean?

## ETHICAL CONSIDERATIONS



- If this barbaric cultural practice didn't exist, as it doesn't in the West (which outlaws FGM), women wouldn't elect it.
- If there's no cultural value attached to FGM, why would any girl want to do it?
- FGM is a reprehensible practice that is not only medically dangerous, resulting in both short- and long-term health problems, but also, by excising the inner labia and clitoris, severely reduces the possibility of sexual pleasure for women—which is of course its point.
- A misguided cultural relativism has tended to overlook these issues, but that kind of relativism isn't acceptable—not when there are health and sexuality issues as well as harm to women.

## TEST CASE: GAMBIAN CULTURE



Three major theories have emerged to attempt to explain the persistence of FGC in Gambia:

- **Feminist theory:** Feminist theory predicts that abandonment of FGC will be correlated with increased rights for women, including improved education for women, protection from domestic violence, property rights, and other factors related to the improvement of women's rights more broadly.
- **Modernization theory:** Modernization theory posits that FGC abandonment is correlated with societal modernization, including improved education in society, increased wealth, increased access to modern media, and other indicators linked with modernization.
- **Convention theory:** Convention theory contends that practices like FGC will only be abandoned by communities or subgroups, rather than by individuals or households, because of the challenges in being the first to abandon traditional practice and face ostracism or rejection from one's community.

## FEMINIST THEORY PREVAILS



TABLE 1: Summary Data Variables

	Would you like your daughter to be circumcised?*	Do you think the practice should continue?***	Are you circumcised?***
Yes	73.73%	71.79%	79.41%
No	26.27%	28.43%	20.59%
Uncertain/Don't Know	0.00%	5.79%	0.00%

Source of data: The Gambia Bureau of Statistics (GBOS), MICS Survey, GMB-MICS2005-2006v1.1

\* Missing 111 values among 9,982 completed surveys

\*\* Missing 66 values among 9,982 completed surveys

\*\*\* Missing 92 values among 9,982 completed surveys

- It is clear that one of the strongest predictors of whether or not a mother would like her daughter to be circumcised is whether or not she is circumcised herself. Those women who are circumcised are about 76.3 percent more likely to want their own daughters to be circumcised.
- Women who are circumcised are approximately 75 percent more likely to believe the practice should be continued.
- Overall, these data suggest that feminist theory goes a long way in explaining the persistence of support for FGC among women in Gambia. Level of education and a woman's circumcision status are particularly significant in predicting support of FGC.
- Data do not strongly support either modernization or convention theories
- Ultimately, any single model may not be adequate to capture the complex set of factors which predict whether or not Gambian women will support female genital cutting

## CONCLUSION



- This study seems to indicate that current development programming, which places greatest faith and emphasis on program development according to convention theory, may be misplaced.
- Greater consideration must be given to feminist development in the society more broadly, rather than community pledges to abandon FGC.
- This finding suggests that, in order to achieve abandonment of FGC, Gambia should place greater emphasis on broader policy changes advancing legal rights of women, including education, property rights, domestic violence protections, and other similar laws focused on expanding and protecting the rights of females.

## ETHICAL CONSIDERATIONS



FGM/C represents an ideal subject for ethical discussion as it challenges virtually all aspects of conventional Western bioethics:

- Autonomy/Self-determination
- Justice (individual and public good)
- Beneficence
- Non-maleficence

Questions to be considered:

- Should FGM/C be considered a public health issue?
- Are biomedical ethics even applicable when the "providers" of FGM/C are not trained medical personnel?
- How does one respect cultural values while invoking human values? Do human values supercede cultural practices?
- What is the value of **cultural relativism** in promoting ethical behaviors? Can education bring enlightenment?

## FGM: A MEDICOLEGAL PERSPECTIVE

**RUWAN J. FERNANDO, MBBS, MS (O&G), FRCOG, MD**  
Imperial College Healthcare – NHS Trust  
London, UK

ICS 2017  
FLORENCE

## Michigan doctor and wife charged over alleged role in performing FGM on girls

Fakrudin and Farida Atar arrested and accused of aiding and abetting ER nurse Jumana Noguwa in performing female genital mutilation at their clinic



FBI agents leave the office of Dr Fakrudin Atar at the Eastern Clinic in Livonia, Michigan, on Friday after completing a search for documents. Photograph: Clarence Saleh / AP

Federal authorities in Michigan have charged a Detroit-area physician and his wife over alleged involvement in a criminal conspiracy that involved performing female genital mutilation (FGM) on young girls.

ICS 2017  
FLORENCE

BBC Your account News Sport Weather iPlayer TV Radio

## NEWS

Home UK World Business Politics Tech Science Health Education Entertainment

UK England N Ireland Scotland Alba Wales Cymru

### Questions raised about prominent FGM campaigner

5 September 2017 UK

A BBC Newsnight investigation has revealed a series of concerns about some aspects of the work of a celebrated FGM campaigner.

Comfort Momoh established one of the UK's first FGM clinics and has recently retired as a midwife from Guy's and St Thomas' Trust in London.

ICS 2017  
FLORENCE

MailOnline News

Home News U.S. | Spain | 718 Shovels | Australia | France | Health | Science | Money | Video | Travel | Fashion | Pledge

Local News | Sport | World News | Life | Business | Crime | Politics | More News | News | December

## British doctor 'performed female genital mutilation on young mother after she gave birth', court told during first trial of its kind

- Woman had undergone female genital mutilation in Somalia as a child
- When she gave birth at London hospital, her FGM stitches were torn
- Court heard doctor was encouraged to sew her up in 'FGM procedure'
- Man who allegedly encouraged procedure is also standing trial
- Doctor had worked at the hospital for a month before the incident
- He denies the charge - which carries a maximum 14-year sentence
- FGM risks the health of tens of millions of women worldwide

By RICHARD SPILLET FOR MAILONLINE  
PUBLISHED: 09:00, 30 January 2015 | UPDATED: 00:38, 30 January 2015

ICS 2017  
FLORENCE

in the UK - How the case came to court

- The events began when the woman, known as AB to protect her identity, presented in labour at the Whittington at about 8am on 24 November 2012.
- It was the birth of her first child, and her labour was progressing fast. By 10.10am, Dr D, the on-call registrar, was bleeped to come to the delivery room.
- Until that moment Dr D had never seen a woman who had undergone FGM, had never been given training on the subject in his undergraduate or postgraduate studies and had no experience of how to carry out a deinfibulation procedure to help women who have undergone FGM give birth safely.
- He was handed the mother's notes, in which midwives had stated she was presenting with type 1 or 2 FGM. Hospital policy dictates that the mother should have been picked up by antenatal teams much earlier in her care, in order to be seen by a specialist team, and referred for a deinfibulation procedure in the months before her due date.
- But midwives had failed to pick up her condition and instead the doctor had to intervene surgically within minutes, with the birth progressing fast and the baby showing signs of distress.

ICS 2017  
FLORENCE

- Making a decision that the foetal heart rate was indicating increasing distress to the baby, he prepared for a delivery with forceps or a suction cap.
- To do so he had to make an incision in order to insert a catheter.
- "AB was in the second stage of labour, she was already 10cm dilated. There was a band of scar tissue that was obstructing her urethra," he said. "I obtained her consent to make a cut, and made an anterior midline cut."
- Dr D said the expectant mother appeared anxious, after coming into the labour ward and finding herself in an emergency situation facing an instrumental delivery.
- The doctor added that he made a single cut, measuring 1.5cm to 2cm.
- During the delivery, with a suction cap, he made another cut, an episiotomy, commonly carried out in childbirth, to allow the baby's head and shoulders to be delivered.
- Within 40 minutes of arriving in the labour room, he safely delivered the baby boy.

ICS 2017  
FLORENCE

- "[The cut] was still bleeding," he said. "It had continually bled since the time we made it and during the delivery. I decided to place a suture in to stop the bleeding.
- I placed a single continuous suture in a figure of eight.
- "I was acting in the patient's best interests to stop the bleeding," he said in evidence.
- It all took about 30 seconds, and immediately afterwards the doctor was called away to carry out an emergency caesarean.
- It was while he was in theatre he began to doubt the procedure he had carried out. He spoke to the consultant on duty, who advised him that the technique he had used was incorrect, but that he should leave the stitch in.



- The Hospital policy, where an African well woman clinic treats about 130 women a year who have undergone FGM, dictates that the labia should never be stitched together during such a repair, because that would amount to reinfibulation, or the restoration of the FGM.
- But Dr D admitted he had not read hospital policy, and realised that what he had done was incorrect.
- "I should not have stitched it with the technique that I used," he said in court. "Now I am well aware of the correct surgical technique."

In the aftermath of the incident, a hospital inquiry examined what had taken place, labelling the event a "serious untoward incident". The inquiry recommended more training for the doctor and a period of reflection. Five months after the incident, he was made a senior registrar.

Meanwhile, the hospital had referred what had taken place in the delivery room to the Metropolitan police as a matter of course because of its concerns.

The referral came at a time of growing public and political pressure on the police and prosecutors over their failure to bring a single prosecution for FGM in the UK since it was made illegal in 1985, legislation that subsequently toughened in 2003.

In May 2013, five months after the woman had given birth, the Met police passed the information they had on the incident to the CPS for guidance. It was one of a handful of cases passed to the CPS for consideration.

In March 2014, 16 months after the baby was born, the CPS announced that Dr D and another man were to be charged in a landmark prosecution.

They made the charges public three days before Director of CPS was to appear before the home affairs select committee to be questioned over her failure to bring a single prosecution for FGM.

The prosecution said he restitched her labia together after the birth, thereby performing FGM. But Dr D said he only put in a small suture at the top of the cut to stop bleeding.

'It is that stitching back together by Dr D, and the woman's husband's insistence or encouragement, which the prosecution says is an offence under the Act.

'The prosecution is the result of an alleged offence under the Female Genital Mutilation Act 2003.

What Dr D did was against the policy of his employer, the Hospital.

That policy is written and available to all midwives, nurses, obstetricians and students at the Whittington and Dr D was expected to be aware of it.

## The Telegraph

Home News World Sport Business Money Comment Culture Travel Life Women Fashion Lifestyle Tech Film  
 Politics Investigation Crime Education Science Earth Weather Health Royal Celebrity Defence Scotland

HOME • NEWS • UK NEWS • LAW AND ORDER

### NHS doctor cleared in less than 30 minutes in first FGM case

Dhanuson Dharmasena, 32, was acquitted by a jury in less than half-an-hour of illegally stitching a young mother up after she gave birth

Dr D, who was a junior registrar at the time he delivered the baby, said he had received no medical training in FGM and had never seen a patient with FGM before AB.

He had also never observed a deinfibulation - the procedure to re-open a woman who has undergone FGM.

But Dr D accepted in hindsight he should have sutured the edges of the cut separately rather than sewing it together, in line with the hospital's FGM guidelines.

Mr Justice S said Dr D had been "badly let down" by systemic failures at the hospital; AB was not referred to an FGM specialist during antenatal appointments and was not given a birth plan or interpreter.

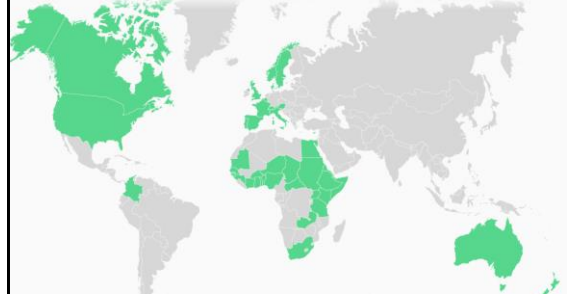

## Discussion:

- Was it the correct decision to prosecute Dr D for FGM/Reinfibulation?
- Did Dr D performed FGM/Reinfibulation?
- Arguments for and against the “Not Guilty” verdict of Dr D

## Which countries ban FGM by law?

Countries with bans on female genital mutilation in 2015



\* As of 2015, 24 US states have specific laws against FGM  
 © StatistaCharts Source: United Nations Population Fund

INDEPENDENT statista

## Criminal Legislation/Decree (year enacted)

**African Nations:**

Benin (2003)  
 Burkina Faso (1996)  
 Central African Republic (1966)  
 Chad (2003)  
 Côte d'Ivoire (1998)  
 Djibouti (1994)  
 Egypt (2008)  
 Eritrea (2007)  
 Ethiopia (2004)  
 Ghana (1994)  
 Guinea (1965, 2000)  
 Kenya (2001)  
 Mauritania (2005)  
 Niger (2003)  
 Senegal (1999)  
 South Africa (2005)  
 Tanzania (1998)  
 Togo (1998)  
 Nigeria (multiple states, 1999-2002)

**Industrialized Nations:**

Australia (6 of 8 states, 1994-97)  
 Belgium (2000)  
 Canada (1997)  
 Cyprus (2003)  
 Denmark (2003)  
 Italy (2005)  
 New Zealand (1995)  
 Norway (1995)  
 Spain (2003)  
 Sweden (1982, 1998)  
 United Kingdom (1985)  
 United States (Federal law, 1996; 17 of 50 states, 1994-2006)

## Legal Measures to Eliminate FGM

Many governments in Africa and elsewhere have taken steps to eliminate the practice of **FGM** in their countries. These steps include laws criminalizing **FGM**, education and outreach programs, and the use of civil remedies and administrative regulations to prevent the practice.

**African Nations**

Eighteen countries have enacted laws criminalizing **FGM**. The penalties range from a minimum of three months to a maximum of life in prison. Several countries also impose monetary fines. There have been reports of prosecutions or arrests in cases involving **FGM** in several African countries, including Burkina Faso, Egypt, Ghana, Senegal, and Sierra Leone.

**Industrialized Nations**

Twelve industrialized countries that receive immigrants from countries where **FGM** have passed laws criminalizing the practice. In Australia, six out of eight states have passed laws against **FGM**. In the United States, the federal government and 17 states have criminalized the practice.

One country—France—has relied on existing criminal legislation to prosecute both practitioners of **FGM** and parents procuring the service for their daughters.

Legislation on Female Genital Mutilation – Crown Prosecution Service UK  
**Female Genital Mutilation Act 2003 in England, Wales and Northern Ireland**  
 and the **Prohibition of Female Genital Mutilation (Scotland) Act 2005 in Scotland.**

1. **FGM is illegal unless it is a surgical operation on a girl or woman irrespective of her age:**
  - (a) which is necessary for her physical or mental health; or
  - (b) she is in any stage of labour, or has just given birth, for purposes connected with the labour or birth.
2. It is illegal to arrange, or assist in arranging, for a UK national or UK resident to be taken overseas for the purpose of FGM.
3. It is an offence for those with parental responsibility to fail to protect a girl from the risk of FGM.

Legislation on Female Genital Mutilation – Crown Prosecution Service UK  
**Female Genital Mutilation Act 2003 in England, Wales and Northern Ireland**  
 and the **Prohibition of Female Genital Mutilation (Scotland) Act 2005 in Scotland.**

4. **If FGM is confirmed in a girl under 18 years of age (either on examination or because the patient or parent says it has been done), reporting to the police is mandatory and this must be within 1 month of confirmation.**

Female genital cosmetic surgery (FGCS) may be prohibited unless it is necessary for the patient's physical or mental health.


All surgeons who undertake FGCS must take appropriate measures to ensure compliance with the FGM Acts.

Re-infibulation is illegal; there is no clinical justification for re-infibulation and it should not be undertaken under any circumstances.



 Royal College of  
Obstetricians &  
Gynaecologists


## Female Genital Mutilation and its Management

Green-top Guideline No. 53  
July 2015



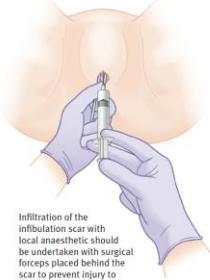
### 1) Type 3 FGM (infibulation)






### Deinfibulation

**2) Infiltration of midline scar with local anaesthetic**




Infiltration of the infibulation scar with local anaesthetic should be undertaken with surgical forceps placed behind the scar to prevent injury to underlying tissues.

**3) Incision of midline scar**

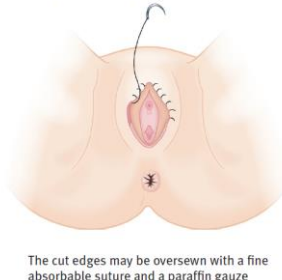


The incision should be made either with scissors or a knife and extended anteriorly until the external urethral meatus is visible.




### Deinfibulation

**4) Suturing of cut edges with absorbable suture**



The cut edges may be oversewn with a fine absorbable suture and a paraffin gauze dressing applied.



### Plan of care for women with FGM in pregnancy

RCOG Guidelines 2015

**Woman with FGM in pregnancy:**  
Referral to designated midwife and/or obstetrician with responsibility for FGM\*  
Consultant-led care

**Child safeguarding risk assessment by midwife or obstetrician:**


- Use risk assessment tool
- Explain law on FGM
- Report to social services or the police if unborn child or related child at risk

**Data recording:**

- Ensure compliance with HSCIC Enhanced Dataset
- Document FGM diagnosis, including FGM type (WHO classification)

**Clinical management plan:**

- Ensure clear documentation
- Preformatted pro formas may be used



### Antenatal

- Use professional interpreter if required (not family member) and explain law on FGM
- Offer referral for psychological assessment and screening for hepatitis C, in addition to routine antenatal screening
- Make clinical assessment of FGM. If de-infibulation is required, agree timing and explain that re-infibulation will not be performed
- Assess other obstetric risk factors and action appropriately
- Agree and document plan for antenatal, intrapartum and postpartum care

- Generally manage as high risk for caesarean section, haemorrhage and perineal trauma
- Some women may be considered low risk and suitable for midwifery-led care if history of previous uncomplicated vaginal delivery
- If de-infibulation is required, ensure that the midwife and obstetrician caring for the woman have received appropriate training
- Perineal tears in women with FGM should be managed in the same manner as in women without FGM

ICS 2017 FLORENCE

## Postpartum

1. Document maternal history of FGM in personal child health record ("Red Book")
2. If delivery of baby girl, notify safeguarding midwife who should inform the GP and health visitor
3. Offer postnatal follow-up if de-infibulation performed intrapartum or if planned de-infibulation did not occur because of delivery by caesarean section
4. Ensure all data required for HSCIC Enhanced Dataset have been recorded

ICS 2017 FLORENCE



## Genital Surgery in the New World

**Tamara Dickinson, MSN, AGPCNP-BC, CURN, CCCN**  
 UT Southwestern Medical Center  
 Dallas, Texas  
 USA

ICS 2017 FLORENCE

## Disclaimer



Not an expert on any of the topics  
 Slides are intended to provide basic information to generate discussion

ICS 2017 FLORENCE

## Male Circumcision


20% of men worldwide  
 Differs for race, religious and cultural reasons  
 Related medical expenses have not been pain in England since 1948 and in Canada since 1970  
 Rate in the United States has decreased from 90% in 1970 to 60% in 2000  
 Burgu et al, 2010

ICS 2017 FLORENCE

## Male Circumcision

The Catholic Catechism says that amputations, mutilations and sterilizations performed on innocent persons is against moral law.  
 Some consider circumcision amputation of the foreskin  
 Webster's defines mutilation: "to cut up or alter radically so as to make imperfect"




ICS 2017 FLORENCE


## Male Circumcision

Routine circumcision?  
 Informed consent?  
 Harm vs benefit?  
 Pain, adequate analgesia/anesthesia?  
 Protective against STDs? Penile cancer?  
 Not without complications?  
 Is it really different than female genital mutilation?

Benatar & Benatar, 2003  
 American Journal of Bioethics



*I don't disagree with Circumcision if the Penis is attached to the man making The Decision.*

**Intersex Surgery** 


Disorders of sexual development encompasses a wide range of external and internal effects evident at birth


External conditions range from phallus in a female child, clitoral hypertrophy, truly ambiguous genitalia, a displacement of the urethral opening lower than the tip of the penis in a male child

Internal conditions include possession of ovaries and testes, androgen insufficiency syndrome

There can also be total disharmony between the chromosomal sex and the anatomic sex of the infant

**DISCUSSION**

**Intersex Surgery** 




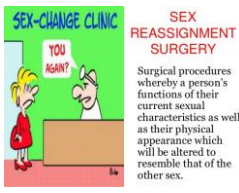
Parents are faced with first having to come to terms with the intersex disorder

These children are often sterile and the grieving is multi-layered

Is there a struggle to reveal what the TRUE sex of the child is?


"Unfathomable otherness"?

**Making Ethical Decisions about Surgical Intervention (MEDSI)** 




Surgical procedures whereby a person's functions of their current sexual characteristics as well as their physical appearance which will be altered to resemble that of the other sex.


The MEDSI is a 1-page ethical decision making flowsheet designed for use by healthcare professionals to guide families facing ethically charged decisions regarding surgical interventions.

**MEDSI Principles** 

Define the ethically charged decision to be made and assemble relevant players in the decision making process	Gather information pertinent to the case
Verbalize emotions and express questions and concerns without judgement	Identify legal issues pertinent to the case
Identify issues of medical necessity and emergency	Analyze information and discuss patient/family preferences
	Decision
	Arrange and provide appropriate follow up

**Intersex Surgery** 

If surgery is postponed temporarily or indefinitely where do people fit in within the rigid two-sex system of medicine and everyday life?



Is non-lifesaving surgical 'correction', often carried out within the first two years of life, unethical?

Does it create a culture of secrecy and shame?

Does it prevent gender identity and cause the child to not achieve psychological well-being?

Intersex ICS 2017 FLORENCE



The slide features a blue header with the text 'Intersex' and the 'ICS 2017 FLORENCE' logo. Below the header, on the left, is a sign for the 'Texas Bathroom Bill' which shows icons of a woman and a man. On the right, there is a photograph of a man in a suit speaking at a podium during a public hearing.

Diversity ICS 2017 FLORENCE




The slide features a blue header with the text 'Diversity' and the 'ICS 2017 FLORENCE' logo. Below the header, there are several logos representing different religions and cultures, including a crescent moon, a yin-yang, a Star of David, a Khanda, a cross, and a Om symbol. A large logo at the bottom reads 'Coeist' with various religious symbols integrated into the letters. The text 'Profits benefit peaceful charities.' is written below the 'Coeist' logo.

ICS 2017 FLORENCE

DISCUSSION

The slide features a blue header with the 'ICS 2017 FLORENCE' logo. The main content area is white with the word 'DISCUSSION' centered in blue capital letters.

Seriously? ICS 2017 FLORENCE



Bing search for "Dallas vaginal rejuvenation" yielded 310,000,000 results

The slide features a blue header with the text 'Seriously?' and the 'ICS 2017 FLORENCE' logo. Below the header, on the left, is a small image of a Bing search result for 'VAGINAL REJUVENATION'. To the right of the image, the text reads 'Bing search for "Dallas vaginal rejuvenation" yielded 310,000,000 results'.

Cosmetic Genital Surgery ICS 2017 FLORENCE

Society is more concerned now than ever before about physical appearance  
Internet access now has a variety of medical experts offering labiaplasty, clitoral hood reduction or enhancement, vaginal rejuvenation  
Is the public communication of aesthetic genital surgery decent? Honest?

Is the medical data to prove claims?  
Is this information balanced? Ethical?  
Is the internet a good source of key information when making the decision for elective surgery?

The slide features a blue header with the text 'Cosmetic Genital Surgery' and the 'ICS 2017 FLORENCE' logo. Below the header, there are two columns of text. The left column discusses societal concerns and internet access to medical experts. The right column poses three questions about medical data, information balance, and internet as a source of information.

Online Content to Promote Genital Cosmetic Surgery: The Themes ICS 2017 FLORENCE

Female genital appearance as important for wellbeing  
Characteristics of women's genitals are important for sex life  
The female body as degenerative, improvable through surgery  
Female genital cosmetic surgery is safe, easy and effective  
Genital diversity as pathological



The slide features a blue header with the text 'Online Content to Promote Genital Cosmetic Surgery: The Themes' and the 'ICS 2017 FLORENCE' logo. Below the header, there are five lines of text. On the right side, there are two small images: one titled 'Candidates for Labiaplasty' showing a woman's lower body, and another titled 'Vaginoplasty Surgery' showing a woman's lower body.



## DISCUSSION

### Lessons Learned

- Ultimately, all of these issues have one theme in common – they affect an individual's self-concept or IDENTITY.
- **Autonomy** should be the ultimate determinate of decision-making in situations involving body alterations, especially when something as intrinsic to personality as gender is involved.
- Ethics also plays a role in situations in which practitioners take advantage of patients' insecurities to promote body change procedures.
- Issues of self become more complicated when the body is altered to match societal, cultural, or religious norms. An individual may wish to participate, but at what cost? And what of the consequences of refusal to obey? The price of **autonomy** is high in either case, but the individual should decide what course to take.

GRAZIE MILLE  
CI VEDIAMO PRONTO

The ICS Ethics Committee