

## Workshop: How to do laparoscopic and robotic promontofixation: theoretical and practical skills.

Workshop Chairs: Andrea Minervini, Florence, Italy  
Domenico Veneziano, Reggio Calabria, Italy

Friday, 15 September 09:30-11:00

Start	End	Topic	Speakers
9:00	9:05	Co-Chair Introduction	Andrea Minervini and Domenico Veneziano
9:05	09:35	Laparoscopic & Robotic Promontofixation: indications and step by step technique	Pierluigi Bove, Andrea Minervini, Domenico Veneziano, Giampaolo Siena, Agostino Tuccio
09:35	10:25	Laparoscopic and robotic Hands on Training session	Pierluigi Bove, Andrea Minervini, Domenico Veneziano, Giampaolo Siena, Agostino Tuccio
10:25	10:30	Closing Remarks and Take Home Message	Andrea Minervini and Domenico Veneziano

### Speaker Powerpoint Slides

Please note that where authorised by the speaker all PowerPoint slides presented at the workshop will be made available after the meeting via the ICS website [www.ics.org/2017/programme](http://www.ics.org/2017/programme) Please do not film or photograph the slides during the workshop as this is distracting for the speakers.

### Aims of Workshop

This workshop is procedure-focused, and will boost and refine delegates theoretical and practical skills and knowledge on laparoscopic and robotic promontofixation. It will provide state-of-the-art Hands-on Training (HoT) courses using pelvic trainer stations and robotic simulators with specific exercises. It will allow the participants to optimize their skills on custom-made models with focus on the main steps of the procedure. Training will be tailored according to their level of expertise in a one to one learning experience.

### Learning Objectives

1. Defining the correct indications for minimally invasive promontofixation.
2. Learning standardized laparoscopic and robotic promontofixation techniques.
3. Improving the participants' laparoscopic and robotic surgical skills using specific simulated tasks, with the main goal of mastering endoscopic promontofixation.

### Learning Outcomes

At the end of the workshop delegates will feel more confident in their practice of laparoscopic and robotic promontofixation.

### Target Audience

Urologist and Gynaecologist wishing to learn the more about the minimally invasive treatment of pelvic organ prolapse.

### Course Requirements

Basic laparoscopic surgical skills  
Robotic console mastering skills

### Hands-on Training session management:

- Each participant will be provided with a mesh at the beginning of the course. They will prepare their mesh during the theory part. 8 scissors + sutures (3-0) will be needed.
- Laparoscopic HoT: 10 minutes for running suture rehearsal + 20 minutes for simulated promontofixation
- Robotic HoT: instrument handling + suturing exercises

### Suggested Learning before Workshop Attendance

- Practice in Pelvic Organ Prolapse (POP) management
- Lap training on the eblus curriculum (<http://uroweb.org/education/online-education/surgical-education/laparoscopy/>)
- Basic Robotic console management.

### Suggested Reading

An International Urogynecological Association (IUGA)/International Continence Society (ICS) joint report on the terminology for female pelvic organ prolapse (POP). Haylen BT1, Maher CF2, Barber MD3, Camargo S4, Dandolu V5, Digesu A6, Goldman HB3, Huser M7, Milani AL8, Moran PA9, Schaer GN10, Withagen MI11. Int Urogynecol J. 2016 Apr;27(4):655-84. doi: 10.1007/s00192-016-3003-y.

Sacrocolpopexy: Surgical Technique, Outcomes, and Complications. Takacs EB1, Kreder KJ2. *Curr Urol Rep.* 2016 Dec;17(12):90.

Minimally Invasive Sacrocolpopexy: How to Avoid Short- and Long-Term Complications. Matthews CA1. *Curr Urol Rep.* 2016 Nov;17(11):81.

Uterine preservation for advanced pelvic organ prolapse repair: Anatomical results and patient satisfaction. Fink K1, Shachar IB1,2, Braun NM1,2. *Int Braz J Urol.* 2016 Jul-Aug;42(4):773-8. doi: 10.1590/S1677-5538.IBJU.2015.0656.

A systematic review and meta-analysis of conventional laparoscopic sacrocolpopexy versus robot-assisted laparoscopic sacrocolpopexy. Pan K, Zhang Y, Wang Y, Wang Y, Xu H. *Int J Gynaecol Obstet.* 2016 Mar;132(3):284-91.

Robot-assisted sacrocolpopexy for pelvic organ prolapse: a systematic review and meta-analysis of comparative studies. Serati M, Bogani G, Sorice P, Braga A, Torella M, Salvatore S, Uccella S, Cromi A, Ghezzi F. *Eur Urol.* 2014 Aug; 66(2):303-18

Outcomes in 450 Women After Minimally Invasive Abdominal Sacrocolpopexy for Pelvic Organ Prolapse. Mueller MG, Jacobs KM, Mueller ER, Abernethy MG, Kenton KS. *Female Pelvic Med Reconstr Surg.* 2016 Jul-Aug; 22(4):267-71.

Laparoscopic versus robotic-assisted sacrocolpopexy for pelvic organ prolapse: a systematic review. Callewaert G, Bosteels J, Housmans S, Verguts J, Van Cleynenbreugel B, Van der Ae F, De Ridder D, Vergote I, Deprest J. *Gynecol Surg.* 2016;13:115-123

Robotic-assisted sacrocolpopexy: technique and learning curve. Akl MN, Long JB, Giles DL, et al. *Surg Endosc* 2009;23:2390–4.

Laparoscopic compared with robotic sacrocolpopexy for vaginal prolapse: a randomized controlled trial. Paraiso MF, Jelovsek JE, Frick A, Chen CC, Barber MD. *Obstet Gynecol* 2011;118:1005–13.

Robot-assisted sacrocolpopexy for pelvic organ prolapse: surgical technique and outcomes at a single high-volume institution. Ploumidis A, Spinoit AF, de Naeyer G, et al.. *Eur Urol* 2014;65:138–45.

**ICS 2017 FLORENCE**

**WORKSHOP 36**

**HOW TO DO LAPAROSCOPIC AND ROBOTIC COLPOSACROPEXY: THEORETICAL AND PRACTICAL SKILLS**

Chair: **Andrea Minervini, MD, PhD** ; \***Domenico Veneziano, MD**  
 Dept. of Urology, University of Florence, Careggi Hospital, Florence, Italy  
 \* Ospedale Reggio Calabria, Italy

UNIVERSITÀ FIRENZE Azienda Ospedaliero Universitaria Careggi

Wednesday 13<sup>th</sup> September 2017

**Andrea Minervini MD, PhD** **ICS 2017 FLORENCE**



**Certificate**

Clinica Urologica – AUC - Università di Firenze

is certified as ERUS Robotic Training Centre

Date: 1 November 2015

Prof. Dr. A. Minervini MD PhD Prof. Dr. D. Veneziano MD PhD

**1. Careggi University Hospital certified as ERUS Robotic Training Centre in 2015**

**2. Proctor for Intuitive Surgical /AB Medica**

**Domenico Veneziano MD** **ICS 2017 FLORENCE**

Affiliations to disclose<sup>†</sup>:

**INTECH innovative training technologies / consultant**

\* All financial ties (over the last year) that you may have with any business organisation with respect to the subjects mentioned during your presentation

Funding for speaker to attend:

Self-funded

Institution (non-industry) funded

Sponsored by:

**ICS 2017 FLORENCE**

**HOW TO DO LAPAROSCOPIC AND ROBOTIC COLPOSACROPEXY: THEORETICAL AND PRACTICAL SKILLS**

WORKSHOP 36


WEDNESDAY 13TH SEPTEMBER 2017

09:00 - 18:30

SPADOLINI G Capacity 150

**SPEAKERS**

- ANDREA MINERVINI WORKSHOP CHAIR
- DOMENICO VENZIANO WORKSHOP SPEAKER
- PIERLUIGI BOVE WORKSHOP SPEAKER
- GIAMPAOLO SIENA WORKSHOP SPEAKER
- AGOSTINO TUCCIO WORKSHOP SPEAKER



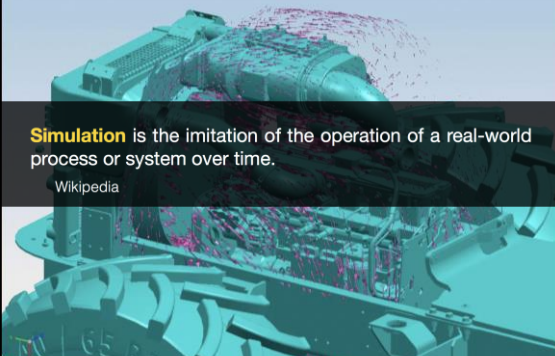
**ICS 2017 FLORENCE**

09:00	<b>INTRODUCTION BY CO-CHAIRS</b> ANDREA MINERVINI DOMENICO VENZIANO
09:05	<b>LAPAROSCOPIC &amp; ROBOTIC PROMONTOFIXATION: INDICATIONS AND STEP BY STEP TECHNIQUE</b> ALL
09:25	<b>LAPAROSCOPIC AND ROBOTIC HANDS ON TRAINING SESSION</b> ALL
10:25	<b>CLOSING REMARKS AND TAKE HOME MESSAGE</b> ANDREA MINERVINI DOMENICO VENZIANO

**ICS 2017 FLORENCE**

<b>AIMS &amp; OBJECTIVES</b>	
LEVEL	Advanced
DURATION	90 minutes
CATEGORY	Pelvic Organ Prolapse
RESEARCH TYPE	Clinical
KEYWORDS	laparoscopic colposacropexy robotic colposacropexy hands on training
TARGET AUDIENCE	Urologist and Gynaecologist wishing to learn more about the minimally invasive treatment of pelvic organ prolapse
AIMS AND OBJECTIVES	This workshop is procedure-focused, and will boost and refine delegates theoretical and practical skills and knowledge on laparoscopic and robotic promontofixation. It will provide state-of-the-art Hands-on Training (HOT) courses using pelvic trainer stations and robotic simulators with specific exercises. It will allow the participants to optimize their skills on custom-made models with focus on the main steps of the procedure. Training will be tailored according to their level of expertise in a one to one learning experience.

How to do laparoscopic and robotic promontofixation: theoretical and practical skills. ICS 2017 FLORENCE



**Simulation** is the imitation of the operation of a real-world process or system over time.

Wikipedia

How to do laparoscopic and robotic promontofixation: theoretical and practical skills. ICS 2017 FLORENCE

Surgical simulation is a **complex science**

it involves :

- cognitive task analysis
- simulator design
- training curriculum design
- simulator validation
- performance assessment
- clinical proficiency assessment
- non-technical skills evaluation and training
- surgical instrument development and testing
- surgical procedure evaluation
- training-the-trainer

How to do laparoscopic and robotic promontofixation: theoretical and practical skills. ICS 2017 FLORENCE



**E-BLUS/BLUS/FLS** **Cadaver**

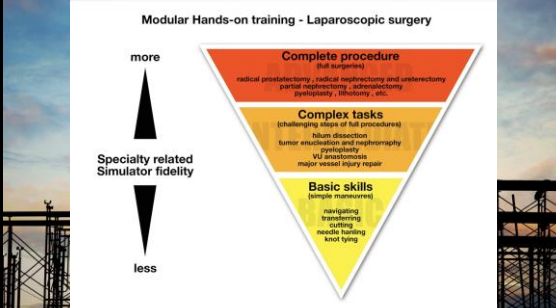
How to do laparoscopic and robotic promontofixation: theoretical and practical skills. ICS 2017 FLORENCE

Modular Hands-on training - Laparoscopic surgery

more

Specialty related Simulator fidelity

less



**Complete procedure** (full surgeries)  
radical prostatectomy, radical nephrectomy and ureterectomy, partial nephrectomy, colorectomy, gastrectomy, lithotripsy, etc.

**Complex tasks** (challenging steps of full procedures)  
ileum dissection, tumor enucleation and nephron-sparing pyeloplasty, VI anastomosis, major vessel injury repair

**Basic skills** (simple manoeuvres)  
navigating, transferring, cutting, needle handling, knot tying

(c) Domenico Veneziano MD FEBU

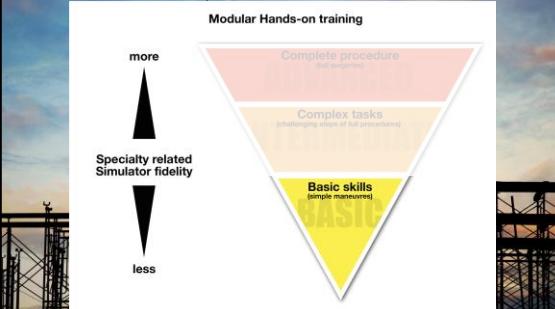
How to do laparoscopic and robotic promontofixation: theoretical and practical skills. ICS 2017 FLORENCE

Modular Hands-on training

more

Specialty related Simulator fidelity

less



**Complete procedure** (full surgeries)

**Complex tasks** (challenging steps of full procedures)

**Basic skills** (simple manoeuvres)

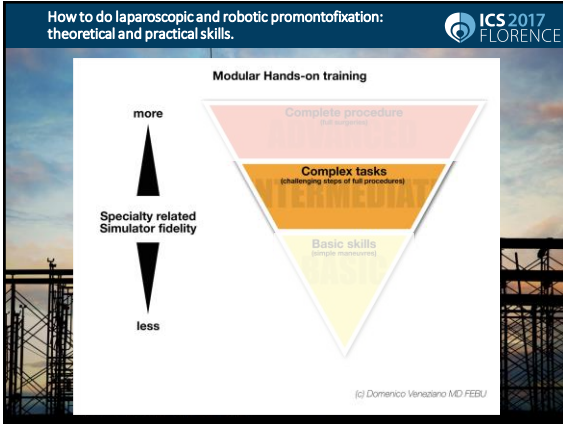
(c) Domenico Veneziano MD FEBU

How to do laparoscopic and robotic promontofixation: theoretical and practical skills. ICS 2017 FLORENCE

**robotic promontofixation: basic skills on BBZ robotic simulator**

- Bi-manual dexterity
- Clutch control
- Needle handling
- Cauterization
- Tissue sparing

Time: 30 mins (7 mins per task)

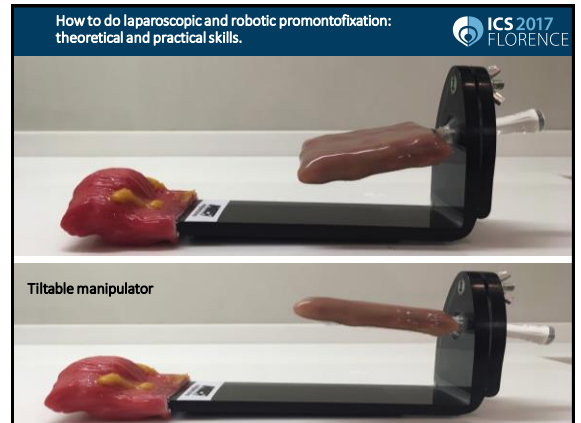
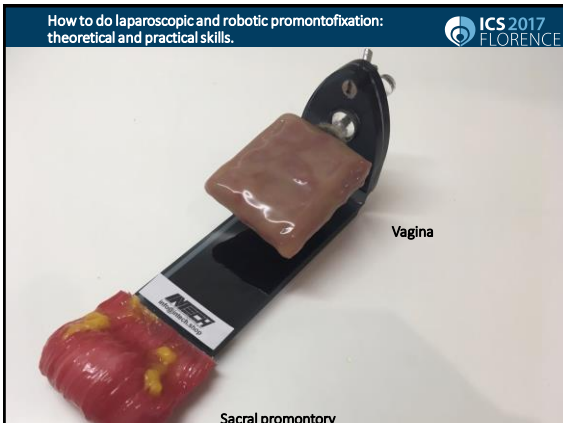


How to do laparoscopic and robotic promontofixation: theoretical and practical skills. ICS 2017 FLORENCE

laparoscopic promontofixation: complex task on INTECH colposacropepy model, custom made for ICS 2017

- Vaginal manipulation
- Suturing
- Mesh preparation
- Mesh placement

Time: 30 mins



**ICS 2017  
FLORENCE**



**LAPAROSCOPIC & ROBOTIC PROMONTOFIXATION:  
INDICATIONS AND STEP BY STEP TECHNIQUE**

**Andrea Minervini, MD, PhD**  
Dept. of Urology, University of Florence, Careggi Hospital, Florence, Italy

**Pierluigi Bove, MD**  
Department of Urology, Tor Vergata University of Rome, Italy

**Laparoscopic Sacrocolpopexy:  
theoretical and practical skills**

Pierluigi Bove M.D.

Assistant Prof. of Urology  
Tor Vergata University of Rome

**PLANNING AND PREPARATION**


- **INDICATIONS**
  - Treatment of choice for women with female genital organ prolapse associated with symptoms of descent or stress/mixed urinary incontinence.
  - Demonstrated success in the settings of vaginal vault prolapse as well as multi-compartment POP
  - Subjective success 74-98% (short FU)

Laparoscopic Sacrocolpopexy.....

**LAPAROSCOPIC & ROBOTIC PROMONTOFIXATION:  
INDICATIONS**

**The best candidate**

- Young women sexually active with
- Vaginal vault prolapse
- Recurrent prolapse
- Severe prolapse



Laparoscopic Sacrocolpopexy.....

**PLANNING AND PREPARATION**

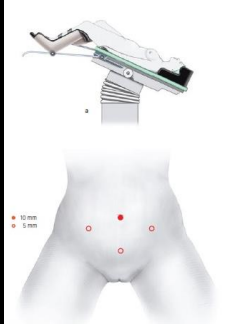
- Benefits of lap. approach include a shorter hospital stay and faster recovery
- Efficacy comparable to abdominal approach and both have surpassed vaginal assisted techniques by virtue of maintaining vaginal length and limiting post-op dyspareunia
- Rectopexy is routinely performed as a combined procedures only in case of clear posterior compartment prolapse

Laparoscopic Sacrocolpopexy.....

**PLANNING AND PREPARATION**

- **SPECIFIC MATERIALS**
  - High-definition laparoscopic stack
  - 10mm 0° laparoscope
  - 2 x 5mm Johann graspers
  - 5mm Maryland dissector
  - 5mm diathermy scissor
  - 5mm bipolar diathermy grasper
  - 5mm needle holder
  - 3 x 5mm laparoscopic trocars
  - 12mm camera port
  - Polypropylene mesh
  - 0 nylon sutures
  - 2/0 Viracyl

Laparoscopic Sacrocolpopexy.....

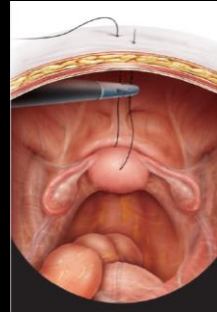


#### Patient Positioning

- Legs fully abducted
- Steep Trendelenburg
- Lap. Stack between legs

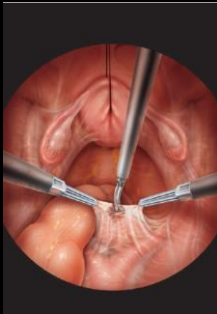
#### Port Placement

- 10-12mm camera port at the umbilicus level (Hasson technique)
- 2 x 5mm on each side at 2/3 distance between umbilicus and ant-sup. iliac spine
- 5mm midway umb-pubis
- 12mmHg Pneumo



#### Pelvic Exposure

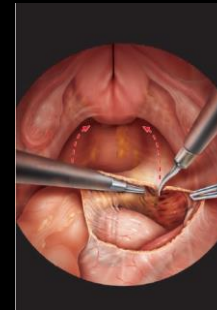
- Mobilize both ascending and descended colon as far as the pelvic brim
- Toldt line is incised by monopolar scissor on both side
- This will allow to leave in place only the bladder, uterus and rectum
- A percutaneous suture on a straight needle will secure the uterus to the abdominal wall



#### Identification of sacral promontory

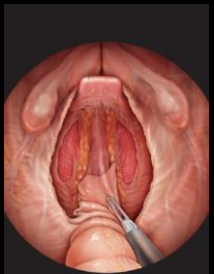- Normally easily identified on the right side
- Accurate position confirmed by tactile feedback
- The peritoneum is incised over the bony prominence taking care of:
  - Ant. Sacral artery ((below)
  - Ureter (lateral)

N.B. this maneuver may be very difficult for obese patients because of fat tissue covering the promontory.....TAKE CARE!!!!!!!  
No during learning curve.....

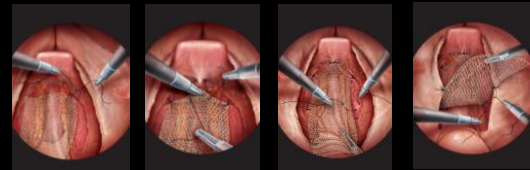


#### Perirectal Dissection

- The peritoneal incision is continued lateral to the rectum until the pelvic floor muscles become visible deep in the pelvis.
- Care is taken to preserve perirectal fat, thus minimising risk of iatrogenic bowel injury or neurovascular damage.



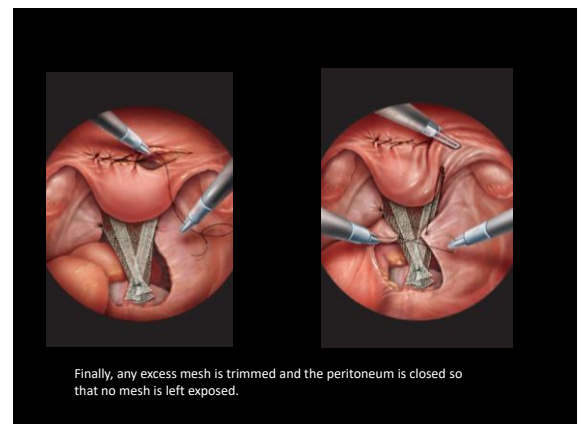
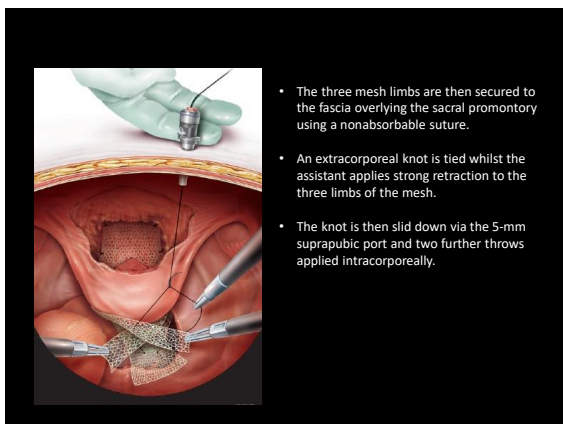
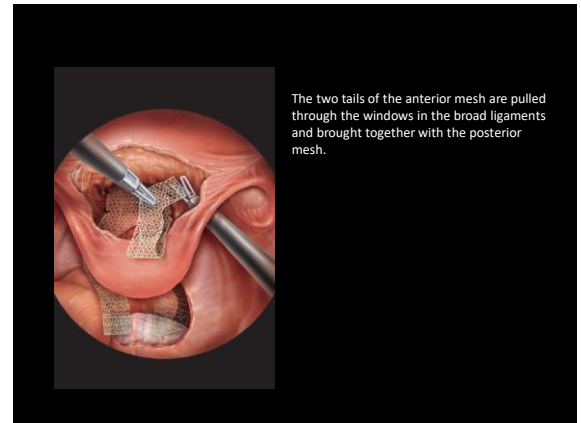
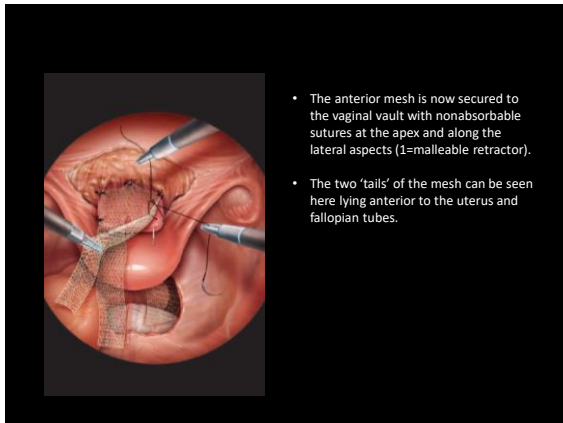
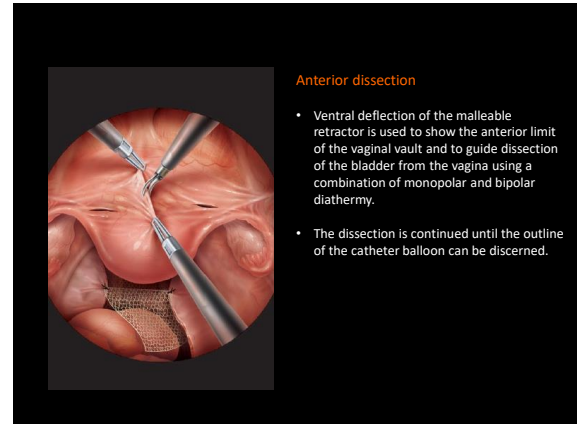
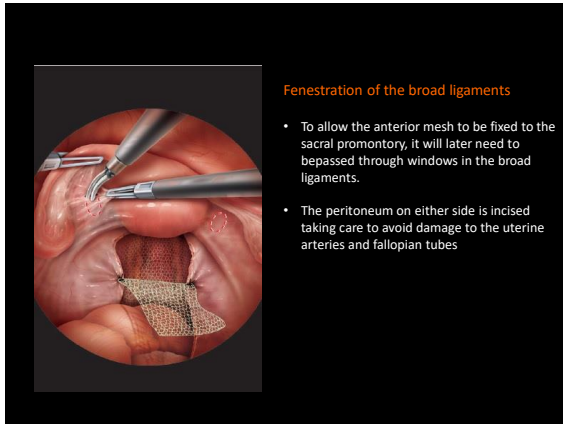
- The process is repeated on the left with gentle cephalad retraction on the rectum aiding dissection.
- Dissection is facilitated by the assistant placing a malleable retractor in the vagina (1) to show the limits of the vaginal wall.
- Ischaemic injury to the vaginal vault is a recognised complication but careful dissection should allow an adequate vaginal wall thickness to be preserved.
- At the end of this stage, good anchor points on the levator ani should be visible bilaterally in preparation for mesh placement.



#### Posterior Mesh placement

- We use a two-part mesh set with pre-cut posterior and anterior components (polypropylene).
- The broad end of the posterior mesh is anchored to the levator ani bilaterally as well as to the vaginal vault in the midline.
- A nonabsorbable monofilament should be used. Intracorporeal suturing is essential at this stage.
- The long tongue of the posterior mesh is left long at this stage and will be trimmed later after fixation to the sacral promontory.
- The posterior element of the procedure is now complete and the suture placed earlier to retract the uterus can be removed.







### Perioperative Care

- A urethral catheter is left in situ until the patient is ambulant; normally 24 h.
- Prophylactic antibiotics, third generation cephalosporin is given at induction.

### From Surgeo to Surgeon

- Sacrocolpopexy should be a relatively straightforward procedure for the experienced laparoscopist.

#### PITFALLS.....

- Identifying the correct planes is essential for
  - a bloodless dissection
  - mesh free from haematoma
  - avoid the risk of neurovascular damage to the rectum

Vaginal wall necrosis can occur many years after surgery, typically 3 or 4 years after. The risk of this can be minimised by ensuring that any sutures placed in the vaginal wall are as superficial as possible, particularly on the posterior wall that has a less reliable blood supply.

Finally, the surgeon (and patient) should always be aware of a risk of postoperative incontinence which may be unmasked by correcting the prolapse.

### From Surgeo to Surgeon

- Sacrocolpopexy should be a relatively straightforward procedure for the experienced laparoscopist.

#### PITFALLS.....

- Identifying the correct planes is essential for
  - a bloodless dissection
  - mesh free from haematoma
  - avoid the risk of neurovascular damage to the rectum

Vaginal wall necrosis can occur many years after surgery, typically 3 or 4 years after. The risk of this can be minimised by ensuring that any sutures placed in the vaginal wall are as superficial as possible, particularly on the posterior wall that has a less reliable blood supply.

Finally, the surgeon (and patient) should always be aware of a risk of postoperative incontinence which may be unmasked by correcting the prolapse.

### LAPAROSCOPIC & ROBOTIC PROMONTOFIXATION: INDICATIONS

It is a **grade A recommendation procedure for vaginal vault prolapse (VVP)**. Further indications include **multicompartment POP and recurrent prolapse after failed vaginal repair**.

For **younger (<60 years old) and sexually active women with symptomatic POP**, SC with mesh provides anatomic pelvic restoration, durable results, less dyspareunia by maintaining vaginal length and axis, and allowing for aseptic mesh placement, thus reducing the risk of mesh infection and erosion.

SC can be performed **laparoscopically with or without robotic assistance**. At present, the laparoscopic SC (LSC) is widely adopted and there are many reports showing durable results (Grade B recommendation). However, **indications and technical aspects are not standardized and vary from country to country** [3].

**Robotic technology** has been marketed based on several possible advantages, including better visualization, extreme maneuverability and greater efficiency and the use of robotic SC (RASC) in the management of female POP appears to be increasing.

### Patient Position

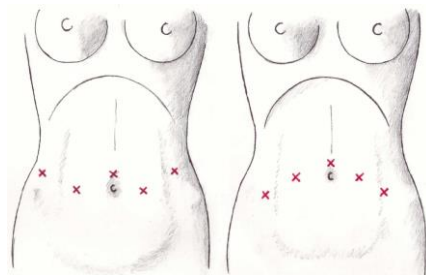
The patient is placed in a **supine position** on a padded vacuum mattress, with open legs. Once the patient is positioned **the perineum should be at the edge of the operating bed** to facilitate the use of the vaginal manipulator or of the malleable vaginal retractor. **Legs should be abducted to help positioning the Da Vinci robot**.

The operating bed must provide a **Trendelenburg position** and **in case of a planned contemporary stress incontinence surgery** the legs of the patient should be movable to a **lithotomic position** at the end of the procedure

### Port Placement

The ports are placed in a **"W"-shaped configuration or in an «arch» configuration** as for pelvic floor surgery, i.e. robotic assisted laparoscopic prostatectomy

The **camera trocar** can be placed at the level of the umbilicus. The operating table is positioned into a **moderate Trendelenburg position around 20°-25° head down**, helping to keep the intestine away the surgical field.



"W"-shaped (left) and "Arc"-shaped (right) ports configuration for Robot-assisted Sacrocolpopexy.

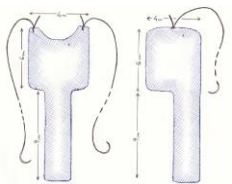
### Surgical Instruments

**Four robotic arms** are generally used, utilizing the camera (with a 0° or a 30° down scope).

The **robotic instruments** employed for the procedure include one Maryland bipolar forceps, a fenestrated Grasper (ProGrasp or Cadieere forceps), robotic monopolar curved scissors (Hot Shears scissors) and one large needle driver.

Furthermore, a vaginal manipulator or a malleable vaginal retractor is used to manipulate the vagina during the procedure.

**Mesh**



A non-absorbable (polypropylene or soft prolene), 15x10 cm wide mesh is normally used and it is advisable to have it prepared beforehand.

**The mesh is cut into two pieces: the anterior and the posterior mesh.**

The total length of both meshes should be approximately 15 cm, any extra length of the tails is of no importance.

### Sacrocolpopexy for POP – Potential (current) Downsides of RASC

- Port Placement
- Douglas Exposure
- Promontory Exposure
- Posterior Dissection
- Posterior mesh fixation to the endoplevic fascia and promontory Douglas closure
- Vesico-vaginal dissection and mesh fixation to the vaginal wall
- Anterior mesh fixation to the promontory
- Peritoneization


**Lack of tactile Feed-Back**

**Costs of RASC** were significantly higher than LSC, although, operational costs collapses when excluding purchase and maintenance of the robotic system getting costs of RASC and LSC comparable

After port placement and docking of the robot, **right iliac vessels, the right ureter, the uterus along with right ovary and tube, the vaginal stump, the Douglas pouch and the rectum** are identified as the most important landmarks

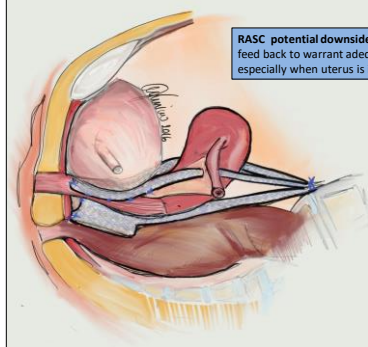
If present, to gain a better exposure of the Douglas pouch, **the uterus is lifted upwards** with either a transcutaneous nylon 0 or 2-0 stitch or with a uterine manipulator. Alternatively, to have a dynamic exposition and traction a ProGrasp forceps can be used.

The **peritoneum** overlays the promontory is then incised on the right side of the sigmoid colon, care is taken to avoid damage to the iliac vessels and the right ureter. Once the peritoneum is opened, **the sacrum and the anterior longitudinal ligament are identified.** The peritoneal incision is extended caudally till the Douglas pouch, on the right side



**RASC potential downside:**  
Lack of tactile feed back


### Colposacropexy: Anterior mesh fixation



**RASC potential downside:** Lack of tactile feed back to warrant adequate traction, especially when uterus is in place

### Sacrocolpopexy for POP - Key issues in support of RASC

**THE FIRST TECHNOLOGICAL INTERFACE BETWEEN SURGEON AND PATIENT**



**Optimal postoperative functional results as LSC**

**Technically easier and short learning curve**

**Reproducibility of the technique**

**Significant body of evidence**

**The first Technological interface between patients and surgeons**

**Future technological improvements to overcome present drawback**


### Laparoscopic vs robotic Sacrocolpopexy: Learning curve

**Robotic-assisted sacrocolpopexy: technique and learning curve**

**Trainee performance at robotic console and benchmark operative times**

Akl et al. reported an overall fast learning curve. **Operative time decreased of 25% after performing the first 10 cases of sacrocolpopexy.**

Geller et Al. reported a learning curve of 20 cases in order to **reduce significantly surgical complications, operative time, open conversions.**





**LAPAROSCOPIC & ROBOTIC PROMONTOFIXATION:  
INDICATIONS AND STEP BY STEP TECHNIQUE**

***THANK YOU FOR YOUR ATTENTION!***




## Uterus preservation

1. Uterus is a “central” element in pelvic statics. Preserving the uterus means preserving normal pelvic anatomy and function
2. Surgery:
  - Easier technique (Less blood loss)
  - Shorter operating time and hospital stay
  - Fewer post-operative complications (less erosions)
  - Major considerations in elderly women or patients with concomitant pathologies
3. Because we must take the woman’s point of view into account

*Hysterectomy and the associated pelvic floor dissection may increase the risk of pelvic neuropathy and disrupt natural support structures such as the uterosacral cardinal ligament complex. Nesbitt 1989*